

Postoperative Delirium averted by EEG-guided opioid-sparing multimodal general anaesthesia

Friedrich Lersch¹, Astrid Kuonen¹, Fredy Rothen¹

¹Department of Anaesthesiology and Pain Medicine, Inselspital, Bern University Hospital, University of Bern, Bern, Switzerland

ABSTRACT

Patients with reduced cognitive reserve often deteriorate into delirium after general anaesthesia (GA). Delirium is a dangerous state, apart from the peril of harming oneself, it seems to open a Pandora's box of grave complications for the ailing patient. Ironically, it is not so rare amongst elderly patients undergoing ophthalmic surgery. While amongst anaesthesiologists the will to forego delirium prevails, we often don't know where to start. This case-study tries to illustrate some clinical venturing points anaesthesiologists might try to improve in patients at high risk for postoperative delirium. The patient, suffering from alcohol-induced Wernicke's encephalopathy had a very high risk of ending up delirious. Of all the many surgeries he had undergone previously, each had landed him in

postoperative delirium. Continued alcohol-dependence kept his risk high. EEG-controlled GA, the use of propofol, dexmedetomidine and melatonin might have kept him away from delirium. The presence of his wife holding his hand, playing his favourite music during preparation until induction of anaesthesia might be helpful. In the end, he came to peacefully, slept 40 minutes more- "like a siesta" he said- and then went home fully conscious and very grateful. Apart from EEG-controlled GA, dexmedetomidine and melatonin, there's little sound data to argue that any of the other interventions alone would have safeguarded him from delirium. Maybe it's time we consider bundles for delirium prevention? Bundles with pharmacological, non-pharmacological, circadian components? After all, it's a jungle out there! And a jungle in here, when you suffer from Wernicke's and are visually impaired.

Key words: Electroencephalography, delirium prevention, emergence delirium, emergence agitation, dexmedetomidine, anaesthesia, general

Introduction

We present the case of 51 year aged patient known for Wernicke's encephalopathy due

Address for correspondence:

Dr Friedrich Lersch
Department of Anaesthesiology
and Pain Medicine, Inselspital,
Bern University Hospital,
University of Bern,
Bern, Switzerland
Email: lamicoofritz@hotmail.com

Article History

Received: 30th April 2021

Revision: 14th May 2021

Accepted: 9th June 2021

Published: 30th June 2021

How to cite this article: Friedrich Lersch, Astrid Kuonen, Fredy Kuonen. Postoperative Delirium averted by EEG-guided opioid-sparing multimodal general anaesthesia. Indian J Ophthal Anaesth 2021;1(2):21-5

to severe and ongoing alcohol dependency of many years. Apart from arterial hypertension and 18 packets cigarette consumption, the patient's history was remarkable for a past motorcycle accident with severe head trauma and complicated fractures of the legs that resulted in multiple surgical procedures. He was undergoing treatment in a pain clinic for his chronic pain connected to the leg's trauma. He had past history of violent bouts of postoperative delirium after surgery which several times aggravated by grand-mal seizures in the context of alcohol deprivation. The patient was scheduled for bilateral cataract surgery of mature cataract. In the premedication clinic, it was clear that undergoing surgery in monitored anaesthesia care (MAC) even in sub-Tenon's block was out of the question due to his uncontrolled movements and exceeding nervousity. General anaesthesia (GA) was scheduled on a day-patient basis. His wife, a retired nurse, stated that she had taken her husband home while being delirious on previous occasions. Returning to his familiar surrounding had always calmed him sufficiently.

Our patient arrived remarkably anxious in the anaesthesia bay accompanied by his wife after receiving 150 mcg clonidine and 6 mg melatonin as oral premedication on the ward. He restated that his wife's presence kept his anxiety at bay. As he was nil-per-mouth and had abstained from alcoholic beverages and cigarettes overnight, we planned to secure his airway by a laryngeal mask airway. Apart from the standard monitoring, a 3-electrode EEG was mounted

on his forehead and 0.3 mcg/kg bodyweight of dexmedetomidine was injected over 10 minutes. During anaesthesia preparation, his favourite music was played via a mobile loudspeaker and the patient kept holding his wife's hand until induction of anaesthesia was completed. Along with the music, the patient was asked to imagine himself in pleasant scenery and to keep breathing in a deep, relaxing manner. The anxiolytic and euphorising effect of propofol induction was described beforehand as part of anxiolytic communication.

Anaesthesia strategy was outlined to be TIVA with propofol and ketamine along with oxybuprocaine local anaesthesia drops as well as two boluses of intravenous lidocaine of 0.75 mg /kg bodyweight before cataract was operated in each eye. Sub-Tenon's block as add-on to GA was decided as default analgesia, should cataracts prove to be too hard to be extracted via phacoemulsification. It was determined that long stretches of EEG-burst-suppression in GA would be avoided and spontaneous breathing be aimed at under still deep, sleep-like anaesthesia. Consequently, GA was determined to be opioid sparing.

Induction was smooth and airway was secured by LMA without problems. After injecting propofol 110 mg iv via infusion pump (TCI Schneider) as well as alfentanil 500 mcg iv and another bolus of 0.15 mcg/kg bodyweight of dexmedetomidine, EEG (figure 1) showed spindle-rich general anaesthesia. Five minutes before incision Ketamine 50 mg iv was injected (figure 1, EEG below at 09.57) I0061935 and propofol

TIVA was maintained at cet 2.30 mcg/ml. Systemic hypertension under anaesthesia with systolic values at 170 mmHg was successfully treated with 2 boluses of 10 mg urapidil. Ventilation was maintained at 60 % FiO₂, at 2 litre fresh-gas-flow and pressure support ventilation. Oxygen saturation, sinus rhythm at 60 bpm and average blood pressure at 145/100 mm Hg were in the normal range for the rest of surgery. Surgery of both eyes was lasted for 25 minutes and was uneventful. Once adequate tidal volume was generated at spontaneous breathing, LMA was removed in deep plane of anaesthesia a few minutes after completion of the 2nd eye's phacoemulsification and IOL insertion. Patient was transferred to his bed while still asleep and awoke 30 minutes later in the presence of his wife. He had good recall of all pre-anaesthesia situations and had no signs of delirium. Three hours after termination of GA, he was able to return home with his wife and spent a good afternoon and enjoyed a good sleep at night. Both the patient and his wife expressed astonishment and relieve of the postoperative trajectory to undisturbed cognition:

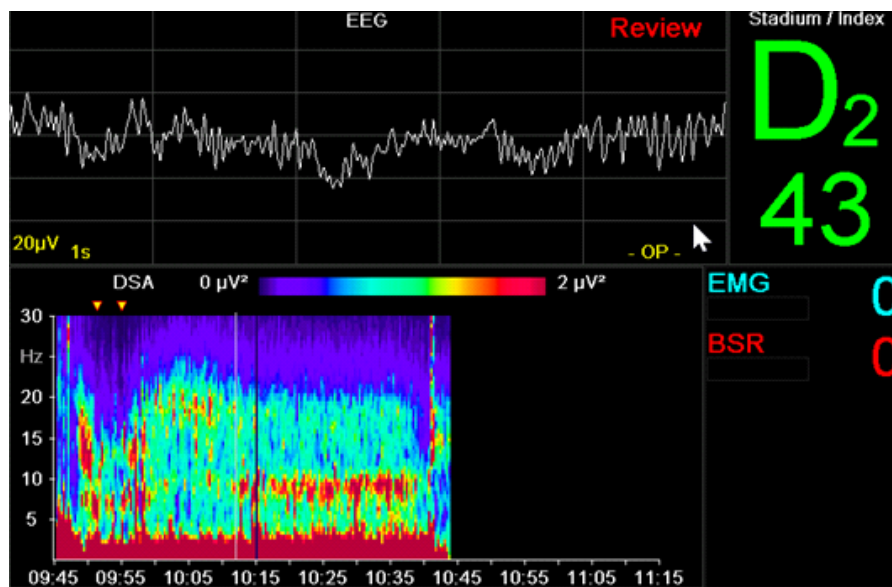


Figure 1: Anaesthesia spindle in raw EEG outlined by red horizontal arrows, mark background alpha activity after propofol-bolus at 9.51 (1st yellow arrowhead) and low beta-activity starting with ketamine bolus at 9.57 (2nd yellow arrowhead). DSA spectrogram illustrates spindle-rich alpha-delta activity from 10.12 until 10.42, followed by smooth emergence to a sleep-like state with faster spindles and EMG-activity in beta range on emergence after 10.42. Red horizontal arrows outline anaesthesia-spindle in the raw-EEG trace.

Discussion

While short duration and minor invasiveness of the ophthalmic procedure certainly helped in avoiding postoperative delirium, several factors deserve short discussion in this patient with a high pre-surgery probability of postoperative delirium. Monitoring perioperative EEG to avoid oversedation seems to be beneficial¹ although overall benefits are still debated². We believe that especially monitoring for anaesthesia-spindles in the raw EEG³ together with spectrogram, dexmedetomidine administration and multimodal analgesia⁴ help in safeguarding patients at risk. A comparison of different quantitative and processed methods vs gauging anaesthesia-depth from raw perioperative EEG is well beyond the scope of this case vignette. Some relevant literature^{5,6,7} is outlined in the bibliography. The role of spindle-rich anaesthesia in reducing postoperative delirium cannot be stressed enough.³

A newer strategy that we adopted recently is the premedication with melatonin.⁸ Current research opening the field to intravenous use of melatonin⁹ may increase our knowledge about beneficial anaesthesia more in the line of the “biomimetic sleep” concept offered by Akeju et al.¹⁰ This might prove especially useful in patients with diminished eye-sight and consequent circadian dysrhythmia predisposing to cognitive complications.¹¹

The ketamine signature is easily recognizable in the DSA spectrogram as an upsurge from the alpha-band (9-15 Hz) into the beta-band (> 15 Hz). Ketamine is an integral part of multimodal or opioid-free anaesthesia.^{12 13} In this case an opioid-sparing technique (ie dramatically reduced opioid administration) was preferred to an completely opioid-free anaesthesia (OFA). Using small boluses of alfentanil reduce brainstem reactions like gagging or coughing on securing the airway. Applying OFA to eye-surgery patient with tracheal intubation again is a wide-ranging discussion for the very reason of brainstem reactions to a tracheal tube can be detrimental to the operated eye. As for the atypical systemic hypertension under sufficient propofol GA, measures were taken to bring systemic pressure back to normal, as choroidal bleeding has been reported in phacoemulsification.¹⁴ The main pathophysiological mechanism to be understood by anaesthesiologists in this context is an increase in transmural pressures of the choroidal vessels.¹⁵ The main difference between dexmedetomidine-dominant multimodal anaesthesia with most other forms of GA is a prolonged sleepiness of the patients. This proves to be a challenge

for the anaesthetists as often sleepiness is interpreted as “abnormal”. A look at the EEG during anaesthesia could easily prove this perception wrong in most cases. NREM-like sleep activity in the post-operative phase seems to lie at the heart of reduced emergence delirium and postoperative delirium observed in dexmedetomidine-treated patients.¹⁶¹⁷

In a clinical environment known for the high incidence of sleep-deprivation and consecutive delirium this might prove an example of “healing sleep”.¹⁸¹⁰

Lastly, the adoption of non-pharmacological elements of anxiolysis before induction (presence of a loved-one, calming music of own choice, imagined scenery, calm breathing etc) is little discussed in ophthalmic anaesthesia but is repeatedly cited as beneficial by literature and patients alike.¹⁹²⁰²¹

References:

1. Fritz BA, Kalarickal PL, Maybrier HR, et al. Intraoperative Electroencephalogram Suppression Predicts Postoperative Delirium. *Anesth Analg* 2016;122:234-42
2. Wildes TS, Mickle AM, Avidan MS. Electroencephalography-Guided Anesthetic Administration and Postoperative Delirium -Reply. *JAMA* - 2019;321:2471-2
3. Hesse S, Kreuzer M, Hight D, et al. Association of electroencephalogram trajectories during emergence from anaesthesia with delirium in the postanesthesia care unit: an early sign of postoperative complications. *Br J Anaesth* 2019;122:622-34

4. Jin Z, Hu J, Ma D. Postoperative delirium: perioperative assessment, risk reduction, and management. *Br J Anaesth.* 2020;125:492-504
5. Marchant N, Sanders R, Sleigh J, et al. How electroencephalography serves the anesthesiologist. *Clin EEG Neurosci* 2014; 45:22-32
6. Bennett C, Voss LJ, Barnard JPM, Sleigh JW. Practical use of the raw electroencephalogram waveform during general anesthesia: The art and science. *Anesth Analg* 2009;109:539-50
7. Palanca BJA, Mashour GA, Avidan MS. Processed electroencephalogram in depth of anesthesia monitoring. *Curr Opin Anaesthesiol.* 2009;22:553-9
8. Campbell AM, Axon DR, Martin JR, Slack MK, Mollon L, Lee JK. Melatonin for the prevention of postoperative delirium in older adults: A systematic review and meta-analysis. *BMC Geriatr* 2019;19:272
9. Andersen LPH, Werner MU, Rosenkilde MM, et al. Pharmacokinetics of oral and intravenous melatonin in healthy volunteers. *BMC Pharmacol Toxicol* 2016; 17:8
10. Akeju O, Hobbs LE, Gao L, et al. Dexmedetomidine promotes biomimetic non-rapid eye movement stage 3 sleep in humans: A pilot study. *Clin Neurophysiol* 2018; 129: 69–78
11. Tan C, Saito N, Miyawaki I, Shiotani H. Preoperative circadian physical activity rhythm and postoperative delirium in cardiovascular surgery patients. *Chronobiol Int* 2020; 37:1059-66
12. Mulier J, Dekock M. Opioid free general anesthesia, a new paradigm? *Best Pract Res Clin Anaesthesiol.* 2017;31:441-3.
13. Brown EN, Pavone KJ, Naranjo M. Special Article: Multimodal General Anesthesia: Theory and Practice. *Anesth Analg* 2018; 127: 1246-58
14. Savastano A, Rizzo S, Savastano MC, et al. Choroidal effusion and suprachoroidal hemorrhage during phacoemulsification: Intraoperative management to prevent expulsive hemorrhage. *Eur J Ophthalmol* 2016;26:338-41
15. Bellows AR, Chylack LT, Hutchinson BT. Choroidal Detachment: Clinical Manifestation, Therapy and Mechanism of Formation. *Ophthalmology* 1981;88:1107-15
16. Janssen TL, Alberts AR, Hooft L, Mattace-Raso FUS, Mosk CA, Van Der Laan L. Prevention of postoperative delirium in elderly patients planned for elective surgery: Systematic review and meta-analysis. *Clin Interv Aging.* 2019;14:1095-1117
17. Palanca BJA, Wildes TS, Ju YS, Ching S, Avidan MS. Electroencephalography and delirium in the postoperative period. *Br J Anaesth* 2017;119:294-307.
18. Wang Y, Shen X. Postoperative delirium in the elderly: the potential neuropathogenesis. *Aging Clin Exp Res* 2018;30:1287-95
19. Cruise CJ, Chung F, Yogendran S, Little D. Music increases satisfaction in elderly outpatients undergoing cataract surgery. *Can J Anaesth* 1997; 44: 43-8
20. Agard E, Pernod C, El Chehab H, Russo A, Haxaire M, Dot C. A role for hypnosis in cataract surgery: Report of 171 procedures. *J Fr Ophtalmol* 2016; 39:287-91
21. Chundamala J, Wright JG, Kemp SM. An evidence-based review of parental presence during anesthesia induction and parent/child anxiety. *Can J Anesth.* 2009; 56:57-70.