



# IJOA

# Indian Journal of Ophthalmic Anaesthesia

Volume 1

Issue 2

Jun 2021

Official Journal of

**Association of Indian Ophthalmic Anaesthesiologists, AIOA**

Old No. 18, New No. 41, College Road, Chennai 600 006,

[www.aioa.org.in](http://www.aioa.org.in)

# Table of Contents

## Indian Journal of Ophthalmic Anaesthesia (Indian J Ophthal Anaesth)

2021 June / Volume 1 / Issue 2

S.No.:	Contents	Page
1	<b>From the Editor's Desk</b> <i>Renu Sinha</i>	1
2	<b>Original Articles</b>	
	<b>Anaesthetic management of children with Congenital Rubella syndrome for ophthalmic procedures: our experience and a review of the literature</b> <i>Renu Sinha, Puneet Khanna, Rajkumar Subramanian, Christopher Dass, Anil Agarwal, Somnath Bose, Mahesh Kumar Arora</i>	02-10
3	<b>Case Report</b>	
	<b>Anaesthesia for patients with Glenn shunt for ophthalmic procedures</b> <i>Shalini Subramanian, Medha Bapat</i>	11-15
	<b>Orbital Exenteration in COVID associated Rhino-Orbital-Cerebral Mucormycosis – An unique Anaesthetic management</b> <i>Prardhana Veerabathula, Rajanarsing Rao Hadigal, George Koshy Pudichira</i>	16-20
	<b>Postoperative Delirium averted by EEG-guided opioid-sparing multimodal general anaesthesia</b> <i>Friedrich Lersch, Astrid Kuonen, Fredy Rothen</i>	21-25
	<b>A child with Moebius syndrome for squint surgery: Anaesthetic management and literature review</b> <i>Ankur Sharma, Varuna Vyas, Renu Sinha</i>	26-30
	<b>Retrobulbar Neurolytic Block with Alcohol for Eye Pain: Experience in 12 Patients and Review of the Literature</b> <i>Oya Yalcin Cok</i>	31-37
4	<b>Brief Communication</b>	
	<b>Peribulbar block - Pros Vs Cons: A debate</b> <i>Jaichandran V V, Keith Allman</i>	38-44
5	<b>Letters to Editor</b>	
	<b>Muthusamy Sub-Tenon's Cannula: An Untold Story II</b> <i>Muthusamy P</i>	45-46

# Indian Journal of Ophthalmic Anaesthesia

## Editorial Board Members

### Editor-in Chief

**Dr Renu Sinha, MBBS MD**

Professor of Anaesthesiology

All India Institute of Medical Sciences, New Delhi

No. 376, Third floor, RP Center, AIIMS, New Delhi 110049

Email: [renusinha@aiims.edu](mailto:renusinha@aiims.edu)

### Associate Editors

**Dr Ankur Sharma MBBS MD**

Associate Professor

Department of Trauma and Emergency (Anesthesiology),

All India Institute of Medical Sciences (AIIMS), Jodhpur

Basni, 2nd Phase, Jodhpur, Rajasthan 342005

Email: [sharmaank@aiimsjodhpur.edu.in](mailto:sharmaank@aiimsjodhpur.edu.in)

**Dr Indu Sen MBBS, MD**

Professor, Anaesthesia and Intensive Care

Post Graduation Institution of Medical Education and Research (PGIMER)

Sector 12, Chandigarh, India 160012

Email: [sen.indumohini@pgimer.edu.in](mailto:sen.indumohini@pgimer.edu.in)

**Dr Jaichandran V V, MBBS, DA, PG. Dip in Biostatistics**

Senior Anaesthesiologist, Sankara Nethralaya

Medical Research Foundation

41/18, College Road, Nungambakkam

Chennai 600006, Tamil Nadu, India

Email: [drvvi@snmail.org](mailto:drvvi@snmail.org)

**Dr Sirisha Senthil, MS, FRCS**

Head of Service, VST Centre for Glaucoma Care

Consultant, Glaucoma and Cataract Services

Kallam Anji Reddy Campus, L V Prasad Marg, Hyderabad – 500 034

Email: [sirishasenthil@lvpei.org](mailto:sirishasenthil@lvpei.org)

### Overseas Editor

**Dr Oya Yalcin Cok, MD EDRA**

Professor of Anaesthesiology

Baskent University, School of Medicine

Department of Anaesthesiology and Reanimation

Adana Dr Turgut Noyan Research and Education Center

Dadaloglu M 2591 S. No:4/A 01250

Yuregir Adana, Turkey

Email: [oycok@baskent.edu.tr](mailto:oycok@baskent.edu.tr)

### Publisher

**Medical Research Foundation**

New No. 41; Old No. 18, College Road, Nungambakkam

Chennai 600006, Tamil Nadu, India

Dear Friends,

The year 2020 was an extremely challenging year for all, forcing everyone to contend with a remarkably gruesome situation. I sincerely hope that everyone is healthy physically as well as mentally and continues to have faith in the Almighty, who gives us strength to fight and the ability to serve the mankind in these difficult times. At this point of time, I consider myself very fortunate to have got the opportunity to announce the release of the second issue of our online journal of IJOA, which includes some of the most pertinent topics relevant to the current scenario.

Along with the coronavirus pandemic, we have been seeing a large number of post-covid sequelae including mucormycosis, neuropathies, thrombosis, depression, decrease pulmonary reserve etc. Hence, in this issue, we are highlighting the management of ocular mucormycosis in the presence of covid related complications.

The story of Muthusamy Sub-Tenon's cannula is being continued in this issue. Arguments between two experts always provide a thorough insight of the subject. Keeping that in mind, this issue has opinion of two experts regarding the pros and cons of peribulbar block for eye surgery. Anaesthesia management of a syndromic child is always challenging therefore this issue also includes review and management of a child with Mobius syndrome for squint surgery. Heart disease patients routinely require ophthalmic surgery for various diseases. This issue incorporates a retrospective study which discusses the types of different ocular pathology, anaesthesia management and complications in children with heart disease coming for ophthalmic surgery. Furthermore, a case series of patients with bidirectional glen shunt for single ventricular pathology, highlighting anaesthesia management in a standalone ophthalmic centre is being discussed.

Experiencing postoperative delirium after surgery is a highly unpleasant experience for the patient. An interesting case report of use of EEG based anaesthesia for smooth recovery is presented. Moreover, A painful blind eye needs an expert intervention so as to relieve the agony of the patient and this issue discusses its treatment with retrobulbar alcohol.

I congratulate and thank all the contributing authors for this issue. I also acknowledge with thanks Mr Deenadayalan, Graphic designer and Mr Theagarajan and his web team, Sankara Nethralaya, Chennai for designing and helping to release the journal on-line.

Last but not the least, we all should look forward, stay optimistic, be hopeful and keep learning.



**Dr Renu Sinha**

Editor

Email ID: editorijoa@gmail.com

Indian Journal of Ophthalmic Anaesthesia

The Official Journal of Association of Indian Ophthalmic Anaesthesiologists



# Anaesthetic management of children with Congenital Rubella syndrome for ophthalmic procedures: our experience and a review of the literature

*Renu Sinha<sup>1</sup>, Puneet Khanna<sup>1</sup>, Rajkumar Subramanian<sup>1</sup>, Christopher Dass<sup>1</sup>, Anil Agarwal<sup>2</sup>, Somnath Bose<sup>3</sup>, Mahesh Kumar Arora<sup>4</sup>*

<sup>1</sup> Department of Anaesthesiology, Pain Medicine & Critical Care, A.I.I.M.S. New Delhi, INDIA, <sup>2</sup> Fortis, Noida, INDIA, <sup>3</sup> Harvard Medical School, Beth Israel Deaconess Medical Center, Boston, MA, <sup>4</sup> Department of Anaesthesiology, ILBS, New Delhi, INDIA

## ABSTRACT

**Background and Aims:** Congenital rubella syndrome (CRS) includes hearing impairment, congenital cataract and congenital heart disease (CHD). Children with CRS may need anaesthesia for imaging as well as for ophthalmic, cardiac and cochlear implant surgeries. The anaesthetic management of children with CRS is challenging because of multiple anomalies. Aim of the study was to analyse incidence of CHD, extra cardiac manifestations, symptoms, drug therapy, mental retardation, associated anomalies and to review the anaesthetic management, postoperative course and complications in CRS patients.

### Address for correspondence:

Dr Puneet Khanna  
Professor,  
Department of Anaesthesiology,  
Pain Medicine & Critical Care,  
A.I.I.M.S. New Delhi, INDIA  
Email-k.punit@yahoo.com

### Article History

Received: 15<sup>th</sup> March 2021

Revision: 10<sup>th</sup> April 2021

Accepted: 6<sup>th</sup> May 2021

Published: 30<sup>th</sup> June 2021

**Methods:** This two year retrospective study was done in an ophthalmic center of a tertiary care hospital. Medical records of children with CRS who underwent ophthalmic procedures were collected, reviewed and analysed and incomplete case records were excluded.

**Results:** Total 46 children (28 infants, 18 >one year old) were included. Congenital cataract was present in 33 (71.7%) children. CHD was diagnosed in 42 (82.5%) children. Patent Ductus Arteriosus (PDA) was present in 32 (69.6%) children; isolated uncorrected PDA (14), corrected PDA (2), pulmonary stenosis (PS) with PDA (5). Twelve children (26.1%) had preoperative history of one or more cardiac symptoms. All patients were stable intraoperatively. Six children had postoperative complications. Three children were managed in post anaesthesia care unit. The three infants (< 60 days old) with uncorrected CHD were shifted to intensive care unit due to respiratory distress and cardiac failure.

**How to cite this article:** Renu Sinha, Puneet Khanna, Rajkumar Subramanian, Christopher Dass, Anil Agarwal, Somnath Bose, Mahesh Kumar Arora. Anaesthetic management of children with Congenital Rubella syndrome for ophthalmic procedures: our experience and a review of the literature. Indian J Ophthal Anaesth 2021;1(2):2-10

**Conclusion:** CRS is a multi-organ dysfunction with CHD; which needs multidisciplinary management for optimization. Symptomatic heart disease is a strong risk factor for postoperative complications.

**Key Words:** congenital rubella syndrome, cardiac anomaly, perioperative management, supra glottic device, ophthalmic surgery, cardiac failure

## Introduction

Congenital rubella syndrome (CRS) is a triad of congenital malformations (Gregg's triad) which includes hearing impairment, congenital cataract and congenital heart disease (CHD).<sup>1</sup> Rubella infection is caused by a Toga virus of the genus Rubi virus and presents with maculopapular rashes.<sup>2</sup> Rubella infection causes multiple congenital malformations known as CRS with an incidence of more than 1,00,000 cases per year.<sup>3</sup> The incidence of congenital cataract with CHD is approximately 95% in CRS patients. CRS may also present with congenital glaucoma, pigmentary retinopathy, purpura, hepatosplenomegaly and jaundice.<sup>4</sup> Infants and children with CRS may need anaesthesia for imaging studies as well as for ophthalmic, cardiac, cochlear implant and cleft palate surgeries. Perioperative management of these children poses a challenge to anaesthesiologist because of presence of multiple anomalies. We reviewed perioperative course of children with CRS, who underwent ophthalmic procedures at our institute

retrospectively. We aimed to analyse CHD, extra cardiac manifestations, symptoms, drug therapy, mental retardation, associated anomalies and to review the intraoperative variables i.e. type of anaesthesia, surgery, analgesia, airway, cardio-respiratory events, recovery, anaesthetic complications and postoperative course in CRS patients.

## Methods

This two year retrospective study was conducted after approval from Institutional ethics committee and Clinical trial registry. Medical records of children with CRS who underwent ophthalmic procedures and examination under anaesthesia (EUA) at our institute were collected and reviewed. The data of children aged less than 10 years of age with CRS were included for analysis and incomplete case records were excluded.

Preoperative as well intraoperative variables were recorded and presented as numbers and percentage [Table1, Table2]. History of limited activity, cyanosis, cyanotic spell, forehead sweating, suck-rest-suck cycle and failure to thrive were recorded for all children. Postoperative course like cardiac failure, respiratory distress, need for ventilation and paediatric intensive care unit (PICU) care were noted. Analysis of data was done using IBM SPSS version 17 (Chicago, IL) and Microsoft excel 2010. A p value of less than 0.05 was considered to indicate statistical significance.

**Table 1: Preoperative Variables of children with CRS for ophthalmic procedures**

Preoperative Variables		Number of children n=46 (%)
Age ( Months)	0 – 1	4 (8.7)
	>1 – 12	24(52.2)
	>12	18 (39.1)
Gender	Male	26 (56.5)
	Female	20 (43.4)
Procedure done	Cataract	33 (71.7)
	Glaucoma	4 (8.7)
	Pseudophakia	1 (2.1)
	Squint	3 (6.5)
	Ocular examination	2 (4.3)
	Aphakia	3 (6.5)
Congenital heart disease	PDA	14 (30.4)
	Device Closed PDA	1 (2.1)
	Ligated PDA	1 (2.1)
	PDA & PS	5 (10.8)
	PDA, PS & AS	2 (4.3)
	PDA & PAH	3 (6.5)
	PDA & ASD	2 (4.3)
	PDA & PFO	2 (4.3)
	PDA, AS & COA	2 (4.3)
	PS	3 (6.5)
	TOF	3 (6.5)
	ASD	1 (2.1)
	MS	1 (2.1)
	MS & PAH	1 (2.1)
	Operated TGA	1 (2.1)
Presence of Cardiac Symptoms		12 (26.1)
On Cardiac drugs		13 (28.2)
Extra cardiac Manifestations		20 (43.4)
Hearing impairment		8 (17.4)
Mental retardation (Yes/No)		15 (32.6)

PDA: Patent Ductus Arteriosus, PS: Pulmonary Stenosis, AS: Aortic stenosis, PAH: Pulmonary Artery Hypertension, ASD: Atrial Septal Defect, PFO: Patent Foramen Ovale, COA: Coarctation of Aorta, TOF: Tetralogy of Fallot, MS: Mitral Stenosis, TGA: Transposition of the Great Arteries,

**Table 2: Intraoperative variables of children with CRS for ophthalmic procedures**

	Intraoperative Variables			Number of children n (%)
Type of anaesthesia	General	Induction technique	Inhalational	38 (82.6)
			Intravenous	6 (13.0)
	Monitored anaesthesia care (MAC)			2 (4.3)
Airway devices			Supraglottic airway device	27 (58.7)
			Endotracheal tube	15 (32.6)
			Face mask	4 (8.7)
Ventilation			Controlled / Assisted	42 (91.3)
			Spontaneous	4 (8.7)
Analgesia			Fentanyl	22 (47.8)
			Fentanyl, Paracetamol	16 (34.7)
			0.5%Proparacaine, 2% lignocaine gel	4 (8.7)
			Fentanyl, Paracetamol, Topical anaesthesia	4 (8.7)
Complications			Yes	3 (6.5)
			No	43 (93.4)

## RESULTS

Total 51 cases of CRS underwent ophthalmic procedure during study period. Total 46 cases were eligible for analysis as records of five cases were incomplete (Table 1). Out of 46 children, 28 were infants and 18 were more than one year old. Congenital cataract was present in 33 (71.7%) children. Congenital cardiac anomaly was diagnosed in 42 (82.5%) children. Patent Ductus Arteriosus (PDA) was the commonest cardiac anomaly (Table 1). Three children had past history of cardiac surgery before ophthalmic procedure.

Twelve children (26.1%) had one or more symptoms of limited activity, cyanosis, cyanotic spells, forehead sweating, suck–rest-suck cycle and failure to thrive. Thirteen children (28.2%) were on cardiac drugs including beta-blockers, diuretics and

digoxin. Extra cardiac manifestations like high arched palate, low set ears or delayed milestones were present in 20 (43.4%) children. Brain-stem evoked response audiometry (BERA) diagnosed hearing impairment in eight children. Mental retardation was present in 15 children.

Three children having PDA with pulmonary arterial hypertension (PAH) received oral midazolam for premedication. All intraoperative variables are tabulated in Table 2. Inhalational induction with sevoflurane was the most commonly used technique (82.6%) followed by intravenous induction in 13.6% cases. Ketamine was used as induction agent in three children with tetralogy of fallot (TOF). Thiopentone was used as induction agent in three children.



For maintenance of anaesthesia, sevoflurane in oxygen and air was used. Two ocular examinations were done under monitored anaesthesia care. A supraglottic airway device (SGD) was the most common airway device used followed by an endotracheal tube (ETT) and facemask. Controlled or assisted ventilation was used in 42 patients, while four were managed with spontaneous ventilation. Perioperative analgesia was administered with proparacaine drops, i.v. fentanyl and paracetamol at the discretion of the attending anaesthesiologist. The intraoperative course was uneventful in 43 children. Six children had perioperative complications. Children experiencing breath holding (n=1), laryngospasm (n=1) and delayed awakening (n=1) were managed successfully in the post-anaesthesia care unit. A two-month-old infant with fever had respiratory distress, as well as two neonates with cardiac failure symptoms with respiratory distress were shifted to ICU (Table 3) and managed with respiratory support and decongestive measures. After discharge from ICU, definitive cardiac intervention was advised.

**Table 3: Postoperative complications in children with CRS after ophthalmic procedures**

Complications	Age / Gender	Weight	Diagnosis	Cardiac Lesion	Cardiac symptoms
Fever Respiratory Distress	2 months/ Male	2.5kg	Cataract	PS ASD PDA	Previous hospitalization Forehead sweating
Respiratory distress Cardiac failure symptoms	25 Days/ Female	1.3 kg	Glaucoma	PDA PS	Tachypnea, respiratory distress, grunting and difficulty with feeding
Respiratory distress Cardiac failure symptoms	21 Days/ Female	1.2 kg	Glaucoma	Large PDA	Tachypnea, respiratory distress, grunting, and difficulty with feeding

Among three children who had intraoperative complications, two children had a PDA and one child had pulmonary stenosis (PS) with PDA. Two months old child with PS, ASD and PDA was managed in NICU and transferred to ward on second postoperative day. Child with PDA and PS was treated in NICU for four days and then discharged from the hospital. Infant who had cardiac failure due to a large PDA were managed successfully in the NICU for six days and discharged from the hospital. The type of cardiac anomaly did not correlate with perioperative complications. Extracardiac manifestations and the presence of mental retardation also did not correlate with perioperative complications. Statistically significant association was found between the presence of cardiac symptoms and postoperative ICU stay

(three of 12 children who had symptoms needed ICU care postoperatively,  $p=0.014$ ).

No association was found between age and incidence of intraoperative events ( $p = 0.787$ ), postoperative complications ( $p = 0.222$ ) and postoperative ICU stay ( $p = 0.222$ ). Sex of the child did not establish significance with intraoperative complications, postoperative complications ( $p=0.075$  and  $1.000$  respectively) and ICU stay ( $p=0.572$ ).

## Discussion

Rubella infection is characterized by rash, fever & lymphadenopathy. Pregnant women with Rubella infection in early pregnancy have an increased incidence of miscarriages, still births and severe congenital anomalies in the new born.<sup>5</sup> Gregg's triad of CRS includes hearing impairment, congenital cataract and CHD. Hearing impairment is the commonest single defect in CRS. At our institute, BERA is done in all patients preoperatively to diagnose hearing impairment in CRS patients. PDA and peripheral pulmonary artery stenosis are the most common cardiac manifestations with a 95% incidence of associated cataract.<sup>1</sup> In our study PDA was the most common cardiac anomaly. Other manifestations include glaucoma, mental retardation, microcephaly, developmental delay. Meningoencephalitis, panencephalitis, radiolucent bone disease, thrombocytopenia, hypothyroidism, diabetes, growth hormone deficiency and renal disorders may be associated with CRS.<sup>4,6</sup> WHO working definitions on various presentations of CRS are shown in Table 4.<sup>7</sup>

**Table 4: WHO working definition [adapted from WHO guidelines]<sup>7</sup>**

Suspected CRS	Clinically Confirmed CRS	Laboratory Confirmed CRS	Congenital Rubella Infection (CRI)
Infant presenting with 1) Heart disease ( $\pm$ ) 2) Suspected deafness ( $\pm$ ) 3) $\geq 1$ of • Microphthalmos • Nystagmus • Leucocoria • Strabismus • Buphthalmos • Diminution of vision	Infant with $\geq 2$ of following 1) Congenital glaucoma 2) Cataract 3) Pigmentary retinopathy 4) Congenital Heart Disease 5) Hard of hearing Or One finding above & 1 below 1) Purpura 2) Splenomegaly 3) Microcephaly 4) Mental retardation 5) Meningoencephalitis 6) Radiolucent bone disease 7) Neonatal jaundice	Clinically confirmed CRS & rubella-specific IgM antibody in blood (100% positive - 0-5 months & 60% positive - 6-11 months)  Rubella virus can be isolated from pharyngeal and urinary samples if facility available. (60% shed rubella virus at age of 1-4 months; 30% at 5-8 months; 10% at 9-11 months)	Infant with no clinical signs of CRS, but who has a positive rubella-specific IgM

Neonates and infants with CRS are infectious as the virus spreads by droplets. Virus can be isolated from the body fluids for a year or more.<sup>8</sup> As cataractous lens is infectious, universal precautions should be followed during surgery.<sup>1</sup>

To date, there are no trials or retrospective reviews to study the anaesthetic management in this special group of population. Few case reports are available emphasizing airway management or maintenance of cardiac grid (preload, systemic vascular resistance, pulmonary vascular resistance, contractility and heart rate) in patients with CHD.<sup>9</sup> Ideally cardiac surgery should be done prior to eye surgery to improve outcomes. Due to various issues like long cardiac surgical waiting lists and financial constraints, we do get children presenting with uncorrected CHD for eye surgery as early cataract and glaucoma surgery is required to prevent amblyopia. In the present study only three children had undergone cardiac surgery.

There are reviews and case reports highlighting anaesthesia management of children with CHD for non-cardiac surgery. Children with uncorrected CHD have a higher incidence of perioperative complications. There is no evidence for the superiority of one anaesthesia technique over other technique.<sup>10</sup> Each case should be evaluated on its individual risk factors. Hariharan U et al reported a successful anaesthesia management of combined surgery for PDA closure with bilateral cataract surgery in a three months old infant with CRS.<sup>11</sup> Ophthalmic surgeries are of short duration with minimal hemodynamic disturbances and minimal blood loss. In CRS, the airway may also be difficult so the difficult airway cart should be available. The need for invasive monitoring should be weighed against complications and

reliability of the value in CHD for the short duration ophthalmic surgery. Whilst echocardiography is valuable for assessing cardiac status perioperatively, its intraoperative use during ophthalmological surgery is not practical. Emergency cardiac drugs should be readily available and an ICU bed should be arranged in case of complicated or symptomatic CHD. Children can be monitored in PACU for 2-3 hours and then a decision can be made for shifting to the ward. In the present study, high arched palate; microcephaly and micrognathia were present in children resulting in difficult mask ventilation necessitating two hand techniques. We were able to manage the airway without complications. This may be attributed to the presence of experienced paediatric anaesthesiologists managing the airway. We preferred inhalation induction with sevoflurane for gradual depression of respiration to evaluate assisted ventilation. In the present study, fentanyl was preferred for analgesia as ophthalmic surgery is a short surgery with less painful stimuli as well as being amenable to topical anaesthesia. Controlled ventilation was achieved with atracurium in view of short duration surgery. SGD was preferred in most of the cases as the intubation and extubation responses could be avoided and IOP does not increase during its insertion and removal. Endotracheal tubes were used in neonates and in older children in case of failed SGA or inadequate ventilation with SGD. Our center is a high-volume center for paediatric ophthalmic surgeries; hence our

observations can't be generalized to other low volume centers. The intraoperative period was uneventful in all the cases.

Two infants (20 days and 24 days old), weighing less than 1.5 kg with large PDA and PHT needed urgent IOP measurement for congenital glaucoma and were not fit for general anaesthesia because of cardiac failure. In these two cases, children were wrapped in cotton towel and a pacifier was used. IOP measurement was done under topical anaesthesia with 0.5% proparacaine and oxygen supplementation.

Recovery was delayed in one child for 45 minutes after the completion of surgery, without any obvious cause such as opioid overdose, incomplete muscle relaxant or hypothermia. We were unable to rule out hypothyroidism as thyroid functions were not done preoperatively. Two case reports of CRS also had delayed recovery and no definitive diagnosis was made in either cases.<sup>12,13</sup> In children with delayed recovery, we did not measure the temperature during perioperative anaesthetic management but we ensured to keep the child warm using blanket, top-head warming device and warm intravenous fluid. This observation needs further study. Laryngospasm after extubation was present in one case which was managed with CPAP and propofol with lowest SpO<sub>2</sub> of 92%. A breath holding spell occurred for 7-10 minutes in one neonate which gradually subsided and extubation was done without complication and further observation was done in PACU.

None of the children required ICU admission after transfer to PACU or the ward.

Three infants required ICU transfer due to respiratory distress and cardiac failure which was evident in the operating room. These infants were less than 60 days old and had uncorrected CHD that was being managed with diuretics. Infants were managed successfully in the NICU and discharged from the hospital.

In this present study we could not establish any association between age, gender, extra cardiac manifestations with the incidence of intraoperative events, postoperative complications and postoperative ICU stay.

The presence of cardiac symptoms in the preoperative period was found to be a strong predictor for perioperative complications. Out of twelve children who had preoperative cardiac symptoms; three (25%) with PDA (2) and PS with PDA (1) had intraoperative complications.

## **Conclusion**

CRS is a multi-organ dysfunction with ophthalmic involvement and CHD. Anesthesiologists should be aware of other clinical manifestations and multidisciplinary management should be undertaken to optimize the clinical conditions before surgery. Children with CRS and symptomatic heart disease are a strong risk factor for perioperative complications.

## **Financial support and sponsorship**

Nil.

## **Conflicts of interest**

There are no conflicts of interest.



## References

1. Vijayalakshmi P, Kakkar G, Samprathi A, Banushree R. Ocular manifestations of congenital rubella syndrome in a developing country. *Indian J Ophthalmol*. 2002;50:307.
2. Parkman PD. Togaviruses: Rubella Virus. In: Baron S, editor. *Medical Microbiology* [Internet]. 4th ed. Galveston (TX): University of Texas Medical Branch at Galveston; 1996 [cited 2016 Sep 25]. Available from: <http://www.ncbi.nlm.nih.gov/books/NBK8200/>
3. Robertson SE, Featherstone DA, Gacic-Dobo M, Hersh BS. Rubella and congenital rubella syndrome: global update. *Rev Panam Salud Pública*. 2003;14:306–15.
4. Surveillance Manual | Rubella | Vaccine Preventable Diseases | CDC [Internet]. [cited 2016 Sep 25]. Available from: <http://www.cdc.gov/vaccines/pubs/surv-manual/chpt14-rubella.html>
4. Surveillance Manual | Rubella | Vaccine Preventable Diseases | CDC [Internet]. [cited 2016 Sep 25]. Available from: <http://www.cdc.gov/vaccines/pubs/surv-manual/chpt14-rubella.html>
5. Tiwari C, Sandlas G, Jayaswal S, Shah H. Hydrocephalus in Congenital Rubella Syndrome: A Case Report. *J Immunol Infect Dis*. 2015;1:108
6. Sever JL, South MA, Shaver KA. Delayed manifestations of congenital rubella. *Rev Infect Dis* 1985 A;7 Suppl 1:S164-9.
7. WHO | Rubella [Internet]. [cited 2016 Aug 16]. Available from: <http://www.who.int/mediacentre/factsheets/fs367/en/>
8. Surveillance Manual | Congenital Rubella Syndrome | VPDs | Vaccines | CDC [Internet]. [cited 2016 Aug 16]. Available from: <http://www.cdc.gov/vaccines/pubs/surv-manual/chpt15-crs.html>
9. Gaur P, Harde M, Gujjar P, Bhadade R. Unique Anaesthesia Problems Encountered In Congenital Rubella Syndrome. *International Journal Of Advances In Case Reports*. 2015;2:686-8
10. White MC. Approach to managing children with heart disease for noncardiac surgery. *Paediatr Anaesth* 2011;21:522-9.
11. Hariharan U, Garg R, Nagpal VK, Pawar M. Combined cardiac and noncardiac surgery in an infant with congenital rubella syndrome: an anesthetic challenge. *Paediatr Anaesth* 2011;21:1168-9.
12. Mishra P K. Delayed recovery in Congenital Rubella Syndrome. letter to editor. *Indian J Anaesth*. 2002;46: 226-8
13. Souki F, Shettar SS. Prolonged respiratory depression after general anesthesia in an adult with congenital rubella syndrome. *Case Rep* 2013;1:46–8.

## Anaesthesia for patients with Glenn shunt for ophthalmic procedures

Shalini Subramanian<sup>1</sup>, Medha Bapat<sup>1</sup>

<sup>1</sup>Department of Anaesthesia, Narayana Nethralaya, Bangalore

### ABSTRACT

Patients with single ventricular physiology (SVP) have a single chamber for systemic and pulmonary venous return. Bidirectional Glenn shunt (BDG) or superior cavopulmonary anastomosis diverts blood from superior vena cava to the pulmonary artery. Patients with this stage of palliation may present for non-cardiac procedures including ophthalmic surgery. They are characterized with low SpO<sub>2</sub> and cyanosis as blood from the inferior vena cava is returned to the systemic circulation without oxygenation. Ophthalmic procedures have certain advantages in being less invasive, absence of major fluid shifts, but many occur in ambulatory centres. The circulatory and ventilator goals in managing patients with BDG shunt for ocular surgery is described.

**Key words:** Bidirectional Glenn shunt, single ventricular physiology, ophthalmic anaesthesia

### Address for correspondence:

Dr Shalini Subramanian  
Consultant Anaesthesiologist  
Department of Anaesthesia  
Narayana Nethralaya Nn-2  
Nh health city, Bangalore, India 560076.  
E-mail id: drshalinisubramanian@gmail.com

### Article History

Received: 25<sup>th</sup> March 2021

Revision: 14<sup>th</sup> April 2021

Accepted: 6<sup>th</sup> May 2021

Published: 30<sup>th</sup> June 2021

### Introduction

Patients with single ventricular physiology (SVP) have a single chamber for systemic and pulmonary venous return. Bidirectional Glenn (BDG) shunt is done as the first or second stage of palliative surgery in these patients.

### Case description

We present anaesthesia management of four patients between 3 and 24 years of age with bidirectional Glenn shunt (BDG) who presented for various ophthalmic procedures.

All patients had good ventricular function of the single ventricle and smooth unobstructed flow through the BDG. One child was operated twice; first for squint surgery and after 8 months for ptosis correction. The case details are listed in Table 1 and the echocardiographic findings are highlighted in Table 2.

They were allowed clear fluids orally until 2 hours prior to surgery to avoid dehydration. They also received maintenance fluid therapy with Ringer lactate intra-operatively. Post-operatively, all were allowed orally within an hour except the one with post-operative vomiting after squint surgery. All patients were discharged home on the first post-operative day.

**How to cite this article:** Shalini Subramanian, Medha Bapat. Anaesthesia for patients with Glenn shunt for ophthalmic procedures. Indian J Ophthalmol Anaesth 2021;1(2):11-5

**Table 1: Patient's demographic and anaesthesia details**

Case	Age/sex/ weight	History and clinical findings	Preopera tive medicati ons	Room air SpO2	Surgery	Ana esth esia	Anaesthesia details	Definitiv e airway	SpO2/Fi O2
1a	13year/ male/ 30 kg	No effort intolerance,	Aspirin, Levetirec etam	83%	Squint	GA	Fentanyl 60µg, Propofol 60mg, Atracurium 15mg	ETT	90% / 0.6
1b		Epilepsy			Ptosis correction			Ambu LMA #2.5	
2	3year/ male/ 12 kg	Normal development al milestones	Aspirin	71%	Squint	GA	Fentanyl 25µg, Propofol 20mg, Atracurium.6mg Controlled Ventilation Air/O2/Sevoflurane POV in PACU maintenance intravenous fluids for 6 hours in PACU	Ambu LMA #2	92% / 0.5
3	24 year/ female/ 40 kg	Dyspnea NYHA Class 2/ no orthopnea	Aspirin	73%	Scleral buckling and PPV with silicon oil insertion	PBB	Fentanyl 50µg Midazolam 2mg	Nasal prong	90% / 3l/min O2
4	10 year/ Male/ 25 kg	No effort intolerance	Aspirin, Enalapril Propranol ol	81%	Lenectomy and anterior vitrectomy for a subluxated lens	GA	Fentanyl 50µg, Midazolam 1 mg, Ketamine 25 mg, Atracurium 10mg Controlled Ventilation Air/O2/Sevoflurane	Ambu LMA#2.5	94%/0.6

**GA: General anaesthesia; PBB: Peribulbar block, CV: controlled ventilation; PPV: pars plana vitrectomy, POV: post-operative vomiting; ETT: endotracheal tube; LMA: laryngeal mask airway**

**Table 2: Echocardiographic findings**

Case	Primary Diagnosis	Ventricular size	Ventricular function	Septum	Valves	Age at which BDG shunt surgery was done
1	Pulmonary atresia	Hypoplastic RV	Good	IVS intact; nonrestrictive ASD, tiny PDA	PV atretic, others normal	8 months
2	Tricuspid atresia	Hypoplastic RV	Good	Nonrestrictive VSD Nonrestrictive ASD	TV atretic Mvprolapsing, AV, PV normal	One month
3	DORV Malposed great arteries	LV normal RV muscle bound	Good	Large VSD Intact IAS	PV stenotic, rest Normal	7 years
4	DORV	LV hypoplastic RV dilated	Good	Large VSD Large ASD Common complete unbalanced AVSD	Common AV valve with moderate regurgitation, severe PS, doming PV, AV normal	21 days

**PA: pulmonary artery; DORV: double outlet right ventricle; PA: pulmonary artery; RV: right ventricle; LV: left ventricle; AV atrioventricular; ASD: atrial septal defect; VSD: ventricular septal defect; AVSD: atrioventricular septal defect; IAS: interatrial septum; IVS: interventricular septum; MV: mitral valve; TV: tricuspid valve; AV: aortic valve; PV: pulmonary valve; BDG: bidirectional Glenn**

## Discussion

SVP is referred to a condition where the normal dual ventricle series circulation is impossible to achieve and a single ventricle is responsible for systemic outflow.<sup>1</sup> The other ventricle may be atretic or hypoplastic. Pulmonary circulation is maintained by passive flow from the superior vena cava (SVC) after BDG shunt. BDG shunt may be preceded by a Blalock taussig (Subclavian artery to pulmonary artery) shunt or PA banding depending on whether the pulmonary flow is low or high respectively. None of our four patients had undergone BT shunt or PA banding. BDG may be followed by the final stage of palliation when the inferior vena cava is connected to the left pulmonary artery (total cavopulmonary connection-TCPC) to achieve a Fontan circulation.<sup>2</sup> Patients awaiting TCPC or in whom unfavourable anatomy or pressures preclude a Fontan's procedure may present for non-cardiac surgery.

BDG shunt is usually done at six months of age when pulmonary pressures are low enough for pulmonary flow to be maintained passively but may be done earlier. The room air SpO<sub>2</sub> in these patients is 75-85% as venous blood from the IVC does not pass through the pulmonary circulation. These patients are on antiplatelet agents or aspirin to prevent shunt thrombosis.<sup>2</sup>

All these patients fall into the high-risk category (White and Peyton classification) due to the presence of SVP, complex heart disease and cyanosis.<sup>1</sup>

During the pre-operative evaluation, it is necessary to understand the unique cardiac physiology of each patient, their stage of palliation and current cardiac status. A close liaison with the attending cardiologist is useful. A careful history regarding effort tolerance, developmental milestones, recent respiratory infection, bleeding diathesis, previous surgery and recovery is helpful. A review of cardiac catheterization data, if available gives valuable information about the various pressures and shunt patency. Complete blood count, coagulation profile, ECG, CXR and echocardiogram are indicated regardless of the nature of surgery. Recent respiratory infection increases the risk of respiratory events during anaesthesia. It is important to avoid anemia as hemoglobin is required to improve oxygen delivery. Polycythemia, increased viscosity and dehydration pose a risk for cerebral venous and shunt thrombosis. It is reasonable to avoid prolonged fasting and continue aspirin therapy in these patients. The presence of ventricular dysfunction, arrhythmias, protein losing enteropathy and thromboembolic episodes should alert the anaesthesiologist to a failing ventricle.<sup>3</sup>

All our patients were above two years, well compensated and posted for ophthalmic surgery which does not involve major fluid shifts, hemodynamic instability or prolonged surgery. Hence they were taken up at our free standing ophthalmology unit within a campus where immediate and specialty cardiac care is also available. No invasive lines were planned or used.



In the operating room, all cardiac, emergency and anaesthetic drugs need to be kept ready and their doses calculated according to body weight. Induction may be intravenous or inhalational. It is vital to avoid air bubbles in intravenous lines. Invasive lines may be planned depending on the nature of surgery and patency of veins.<sup>4</sup> Central line, if needed should be placed in the femoral vein.<sup>2</sup> The chief circulatory goals are to avoid dehydration, keep afterload low to maintain forward flow and maintain low pulmonary vascular resistance. Tachycardia and arrhythmias are poorly tolerated and Qp/Qs should be maintained between 0.7 and 1.5. Spontaneous ventilation keeps PVR low, improves cardiac output and pulmonary blood flow but controlled ventilation allows improved oxygenation and minute ventilation. Nitrous oxide is best avoided due to its tendency to increase PVR and risk of air expansion.

The SpO<sub>2</sub> usually increases after induction due to improved cardiac output and decreased peripheral oxygen extraction. Nevertheless, an SpO<sub>2</sub> >90% may also be suggestive of pulmonary over-circulation with the concomitant risk of pulmonary edema.<sup>5</sup> Infective endocarditis prophylaxis is indicated in these patients for procedures that cause bacteremia.<sup>6</sup>

Brown et al reported that 1.8% of patients with SVP undergoing non-cardiac surgery had an adverse anaesthesia event with 60.8% needing post-operative cardiac ICU care. The adverse events identified included hypotension, bradycardia, arrhythmias, ST-T changes and cardiac arrest.<sup>7</sup>

In conclusion, it may be said that patients with BDG shunt are considered high risk and are best managed in tertiary care centres with facilities for transfer to cardiac ICU, if required. A thorough understanding of the patient's cardiac physiology is crucial in managing anaesthesia for non-cardiac surgery.

### Financial support and sponsorship

Nil.

### Conflicts of interest

There are no conflicts of interest.

### References

1. White MC, Peyton JM. Anaesthetic management of children with congenital heart disease for noncardiac surgery. *Contin Educ Anaesth Crit Care Pain J* 2012;1:12
2. Gupta B, Gupta A, Agarwal M, Gupta L. Glenn shunt: Anaesthetic concerns for a non cardiac surgery. *Northern Journal of ISA* 2017;2:36-42.
3. Yuki K, Casta A, Uezono S. Anesthetic management of noncardiac surgery for patients with single ventricle physiology. *J Anesth* 2011;25:247-56.
4. Alatassi A, Mulero SF, Massoud N, Alzayer Z, Mahmoud AH. A case series of different anesthesia approaches for single ventricular physiology patients in various stages of palliation underwent noncardiac procedures. *Saudi J Anaesth* 2018;12:629-33.
5. Leyvi G, Wasnick JD. Single-ventricle patient: Pathophysiology and anesthetic management. *J Cardio thorac Vasc Anesth* 2010;24:121-30.

6. Wilson W, Taubert KA, Gewitz M, et al. Prevention of infective endocarditis: A guideline from the American Heart Association Rheumatic Fever, Endocarditis, and Kawasaki Disease Committee, Council on Cardiovascular Disease in the Young, and the Council on Clinical Cardiology, Council on Cardiovascular Surgery and Anesthesia, and the Quality of Care and Outcomes Research Interdisciplinary Working Group. *Circulation*. 2007;116:1736–54
7. Brown ML, DiNardo JA, Odegard KC. Patients with single ventricle physiology undergoing noncardiac surgery are at high risk for adverse events. *Ped Anes* 2015; 25 846-51



## Association of Indian Ophthalmic Anaesthesiologists

**Organization in which Anaesthesiologists, Ophthalmologists and  
Clinicians involved in Eye care can share their views under one roof**

**To know more about its Objectives and Privileges of becoming its MEMBER,  
<http://aioa.org.in/>**

**Dr Parakh SC**  
President

**Dr Jaichandran VV**  
Secretary

**Dr Kannan R**  
Treasurer

## Orbital Exenteration in COVID associated Rhino-Orbital-Cerebral Mucormycosis – An unique Anaesthetic management

Prardhana Veerabathula<sup>1</sup>, Rajanarsing Rao Hadigal<sup>1</sup>, George Koshy Pudichira<sup>1</sup>

<sup>1</sup>Consultant Anaesthesiologist, L.V. Prasad Eye Institute, Hyderabad, India.

### ABSTRACT

Mucormycosis is a fulminant, opportunistic fungal infection most commonly seen in diabetics and immunocompromised individuals. It is a highly lethal, locally invasive with propensity to involve multiple organs. Successful management of mucormycosis largely depends on early diagnosis, broad surgical debridement of infected tissue and rapid administration of systemic antifungal therapy. Here we present anaesthetic challenges encountered in a 37 year old male, post-covid status patient with rhino-orbital-cerebral-mucormycosis posted for orbital exenteration.

**Key words:** Rhino-orbito-cerebral mucormycosis, anaesthetic management, mortality nephrotoxicity, systemic amphotericin B

### Introduction

Rhino-Orbital-Cerebral Mucormycosis (ROCM) is a relatively rare fungal infection with severe morbidity and high mortality.<sup>1</sup>

### Address for correspondence:

Dr Prardhana Veerabathula, MD  
Consultant Anaesthesiologist  
L.V. Prasad Eye Institute, India.  
pveerabathula@gmail.com

### Article History

Received: 1<sup>st</sup> June 2021

Revision: 8<sup>th</sup> June 2021

Accepted: 18<sup>th</sup> June 2021

Published: 30<sup>th</sup> June 2021

Its locally invasive in nature with propensity to involve multiple organs, warrants early diagnosis and multidisciplinary approach of management.<sup>2,4</sup> The rise in ROCM cases in Covid-19 Pandemic in India is no less than an epidemic.<sup>3</sup> We present the anaesthetic management of case of Right ROCM posted for Orbital Exenteration.

### Case Report

A 37 year old male patient presented with right sided complete ophthalmoplegia with no light perception for 5 days (Figure 1a, b). Patient had history of COVID-19 infection 6 weeks prior (COVID pneumonia with Corads 5 CT severity Score 9/25), and received 40mg IV Methyl Prednisolone daily for a week (cumulative 280mg).

He was recently diagnosed to have Type II Diabetes and had undergone endoscopic sinus debridement for suspected Sino-Orbital Mucormycosis under general anaesthesia. At presentation, he was on Amphotericin-B 800mg/day. His C-reactive protein was 14.8mg/L, serum potassium was 2.8mEq/L, Serum Creatinine was 2.1mg/dl, HbA1c was 12.7%, and random blood sugar was 368mg/dl. Hemoglobin was 10.9gm/dl, ECG was within normal limits, and 2D Echo was normal with EF 62%. The patient was posted for right eye orbital exenteration (Lid sparing).

**How to cite this article:** Prardhana Veerabathula, Rajanarsing Rao Hadigal, George Koshy Pudichira. Orbital Exenteration in COVID associated Rhino-Orbital-Cerebral Mucormycosis – An unique Anaesthetic management. Indian J Ophthal Anaesth 2021;1(2):16-20

On pre-anaesthetic examination, airway assessment revealed diffuse edema of the oral cavity mucosa, and the mouth opening was 2 fingers, modified Mallampati Grade III. Patient's effort tolerance was poor Grade 3 dyspnea with room air SpO<sub>2</sub> 94-95%.

In view of recent post COVID pneumonia, uncontrolled diabetes and impaired renal parameters with hypokalemia (expected side effects of Amphotericin-B), the patient was considered high risk for general anaesthesia. This was discussed with the primary orbital surgeon, who decided to perform orbital exenteration under tumescent local anaesthesia and peri-orbital nerve blocks. Sedation, if required, was also planned.

All cardiorespiratory monitoring such as pulse oximeter, NIBP and ECG, was utilized, and intravenous access was obtained with 20G cannula. Oxygen was administered through nasal prongs.

Dexmedetomidine 30mcg loading dose was given IV over a period of 10 mins and IV Fentanyl 60mcs were given for sedation and analgesia.

After timeout, painting and draping, the right eye was prepped and the peri-orbital region was given local infiltration with Klein solution covering most of the innervating nerves (supratrochlear, supraorbital, infratrochlear, infraorbital, anterior ethmoidal, zygomaticofacial, and zygomatico-temporal nerves) as shown in Figure 2.

Throughout the procedure, patient hemodynamics were maintained within the normal limits and the patient tolerated the procedure without any discomfort.

## **Tumescent Anaesthesia**

Very few case reports suggest use of intravenous sedation along with Local anaesthesia for Orbital exenteration.<sup>5</sup> We used Tumescent Anaesthesia- infiltrate as you go technique using Klein solution along with Dexmedetomidine sedation with a bolus dose of 30mcg IV (0.5mcg/kg body weight). The Klein solution is a mixture of local anesthetic, epinephrine and saline. It was prepared by adding a 50 ml of plain 1% lidocaine and 1ml of 1:1000 epinephrine to a standard 1-L bag of sodium chloride solution. The resulting mixture contains 0.05% lidocaine and 1:1,000,000 epinephrine.

To this, 10 mEq of sodium bicarbonate is added to alkalinize the solution. Since deep orbital injection is not possible due to the orbital pathology (in this case mucormycosis), superficial infiltration of upper eyelid, lower eyelid and canthal region along the entire orbital rim was performed with approximately 5-15ml of Klein solution (fig. 2). Surgery was commenced within 15 minutes. As the dissection proceeded beyond the orbital rim (into the orbital cavity), top-up was injected as 2-3 ml of Klein solution until the surgery was completed. The patient tolerated the procedure well with good sedation and stable hemodynamics. Early post-operative recovery and wound healing was uneventful (Figure 1d)

## **Discussion**

The classical features of mucormycosis are angio-invasion, thrombosis, infarction and necrosis.



Rhino- Orbito- Cerebral Mucormycosis though a rare fungal opportunistic infection, has significant morbidity and very high mortality. It is defined as a medical emergency requiring rapid control of underlying disease, early initiation of liposomal Amphotericin B (AmB), and surgical debridement. The definitive early therapeutic intervention curtails the spread.<sup>6</sup>

Orbital exenteration is an extensive surgery causing facial disfigurement involving removal of the entire contents of the orbit with or without removal of eye lids.<sup>5</sup> Orbital surgeries are universally performed under general anaesthesia, and same is the case for orbital exenteration.

ROCM cases pose unique challenges for general anaesthesia, see Figure 3. Patients present with uncontrolled underlying conditions (diabetes mellitus, malignancies or immunocompromised state) and sepsis leading to hemodynamic instability, difficult airway concerns due to palatal perforation, extensive disease involvement causing mucosal and submucosal edema in and around the airway. Hypokalemia, hypomagnesemia, fever with chills, dyspnea and hypotension are common side effects of Amphotericin B which need much attention as cases have been reported to have arrhythmias and ventricular ectopics immediate post induction.<sup>4</sup> In addition, the post – COVID-19 status of these patients give rise to various concerns as in the extent of pulmonary involvement, (CT scores) ARDS and multi-organ-dysfunction, the use of steroids per se making control of blood sugars a challenge and use of anticoagulant

in severe Covid also put these patients at a higher risk of bleeding.<sup>6</sup>

### **The challenges we had to overcome in our patient were**

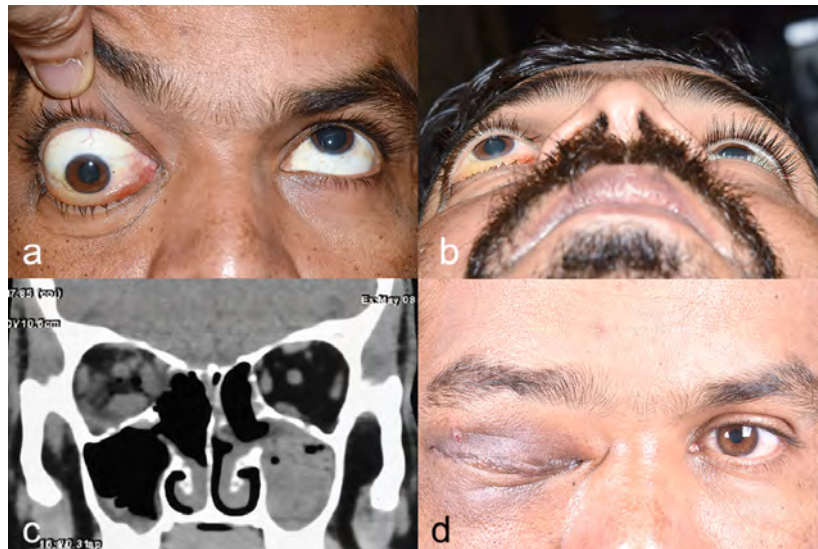- Difficult airway –mucosal edema with limited mouth opening (2 fingers)MPG-III
- Post Covid pneumonia recovered with Corads 5 CT severity Score 9/25
- Uncontrolled blood sugars (random) 386mg/dl and HbA1c of 12.7
- Hypokalemia with serum potassium 2.8mEq/l
- Renal impairment serum creatinine 2.1mg/dl

Dexmedetomidine is a sedative agent via  $\alpha 2$  adrenergic agonist, provides light sleep- like sedation with little respiratory suppression. Dexmedetomidine is an established adjuvant in ophthalmic anaesthesia for peribubar block or for reduction of IOP in glaucoma cases.<sup>8,9</sup> Its considered beneficial for sedation in Covid patients on ventilator with multiorgan failure due to its neuro, cardio and renoprotection.<sup>7</sup>

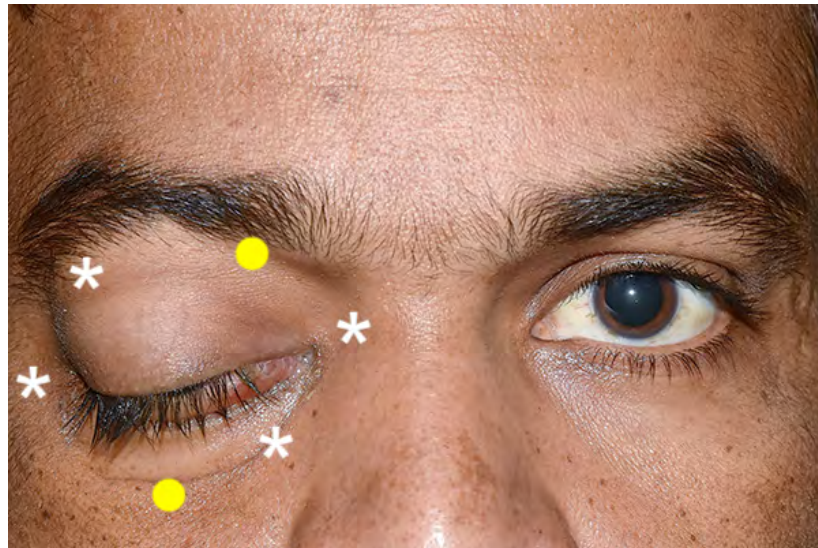Tumescent local anaesthesia has been sparsely reported in ophthalmic plastic surgery.<sup>10</sup> The tumescent technique is associated with less discomfort, allows a more rapid postoperative recovery, avoiding the overall general anaesthesia risk.

### **Conclusion**

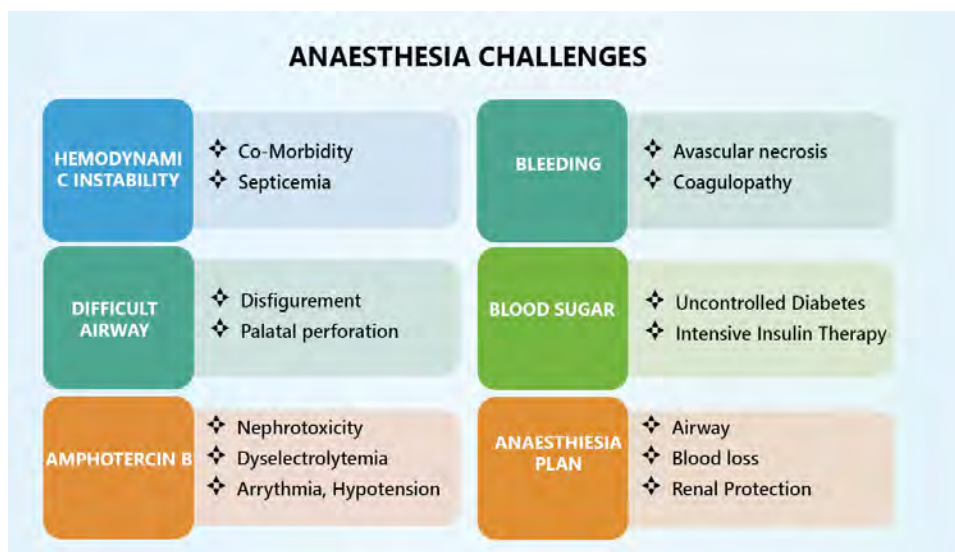
The rise in Covid associated ROCM has been a challenge for management. These patients need repeated anaesthesia for multiple sinus debridement and finally facial disfiguring surgeries which requires a multidisciplinary approach.



**Figure 1.** A 37-year-old male with right complete ophthalmoplegia with no light perception since 5 days (a,b). Note the complete ophthalmoplegia and proptosis. Computed tomography scan of the orbit showed clear sinuses (following debridement), and diffuse involvement of the orbital soft tissues (c). Same patient, 2 weeks following an eyelid sparing exenteration performed under tumescent local anaesthesia showing healthy wound(d).



**Figure 2.** Tumescent Anaesthesia- infiltrate as you go technique for performing Orbital exenteration under local anaesthesia. Supraorbital and infraorbital nerve blocks were given first (yellow dot), followed by multiple periocular sub-cutaneous infiltration of Klein solution (asterix).



**Figure 3.** Anaesthesia challenges in a case of ROCM

Ophthalmic anaesthetist involved in anaesthetic management of these patients coming to tertiary eye care center need to consider the risk and benefits of the anaesthesia options available. The Tumescant Anaesthesia and Dexmedetomidine sedation offer a better patient tolerance and surgical outcomes for patients with multiple co-morbidities.

#### **Financial support and sponsorship**

Nil.

#### **Conflicts of interest**

There are no conflicts of interest.

#### **References**

1. Hirabayashi KE, Idowu OO, Kalin-Hajdu E. Invasive fungal sinusitis: risk factors for visual acuity outcomes and mortality. *Ophthalmic Plast Reconstr Surg* 2019;35:535–42.
2. Ravani SA, Agrawal GA, Leuva PA, Modi PH, Amin KD. Rise of the phoenix: Mucormycosis in COVID-19 times. *Indian J Ophthalmol.* 2021;69:1563-8.
3. Sen M, Lahane S, Lahane TP, Parekh R, Honavar SG. Mucor in a Viral Land: A Tale of Two Pathogens. *Indian J Ophthalmol.* 2021;69:244-52.
4. Kulkarni PK, Reddy NB, Shrinivas B, Takkalki VV. Anesthetic considerations in the management of Mucormycosis. *Int J Med Public Health* 2015;5:387-90.
5. Manjunath Timmappa Bhat, Harihar V Hedge, M C B Santhosh, and Raghavendra P Rao. Orbital Exenteration under trigeminal Block : an innovative method of regional anaesthesia *Saudi J Anaesth.* 2013;7:470-3.
6. Deepak Garg, Valliappan Muthu, Inderpaul Singh Sehgal, Raja Ramachandran, et. Al. Coronavirus disease (Covid – 19) Associated Mucormycosis (CAM): case report and systematic review of literature. *Mycopathologia* 2021;186:289-98
7. Hailin Zhao, Roger Davies, and Daqing Ma. Potential therapeutic value of dexmedetomidine in COVID -19 patients admitted to ICU. *British Journal of Anaesthesia* 2021;126(1):e33-e52.
8. Sirisha Senthil, Keerthi Burugupally, Umashankar Rout, Harsha L Rao, Rashmi Krishnamurthy, Swathi Badakere , Nikhil Choudhari, Chandrasekhar Garudadri. Effect of Intravenous Dexmedetomidine on Intraocular Pressure in Patients Undergoing Glaucoma Surgery Under Local Anesthesia: A Pilot Study. *J Glaucoma* 2020;29:846-50.
9. Shalini Subramanian, Medha Bapat, Thirumalesh MB, Sherine Braganza. Magnesium versus dexmedetomidine as adjuvant to local anaesthetic in peribulbar block for vitreoretinal surgery. *Indian J Ophthal Anaesth* 2021;1:3-12.
10. Honavar SG. Code Mucor: Guidelines for the Diagnosis, Staging and Management of Rhino-Orbito-Cerebral Mucormycosis in the Setting of COVID-19. *Indian J Ophthalmol.* 2021;69:1361-5.



# Postoperative Delirium averted by EEG-guided opioid-sparing multimodal general anaesthesia

*Friedrich Lersch<sup>1</sup>, Astrid Kuonen<sup>1</sup>, Fredy Rothen<sup>1</sup>*

<sup>1</sup>Department of Anaesthesiology and Pain Medicine, Inselspital, Bern University Hospital, University of Bern, Bern, Switzerland

## ABSTRACT

Patients with reduced cognitive reserve often deteriorate into delirium after general anaesthesia (GA). Delirium is a dangerous state, apart from the peril of harming oneself, it seems to open a Pandora's box of grave complications for the ailing patient. Ironically, it is not so rare amongst elderly patients undergoing ophthalmic surgery. While amongst anaesthesiologists the will to forego delirium prevails, we often don't know where to start. This case-study tries to illustrate some clinical venturing points anaesthesiologists might try to improve in patients at high risk for postoperative delirium. The patient, suffering from alcohol-induced Wernicke's encephalopathy had a very high risk of ending up delirious. Of all the many surgeries he had undergone previously, each had landed him in

postoperative delirium. Continued alcohol-dependence kept his risk high. EEG-controlled GA, the use of propofol, dexmedetomidine and melatonin might have kept him away from delirium. The presence of his wife holding his hand, playing his favourite music during preparation until induction of anaesthesia might be helpful. In the end, he came to peacefully, slept 40 minutes more-“like a siesta” he said- and then went home fully conscious and very grateful. Apart from EEG-controlled GA, dexmedetomidine and melatonin, there's little sound data to argue that any of the other interventions alone would have safeguarded him from delirium. Maybe it's time we consider bundles for delirium prevention? Bundles with pharmacological, non-pharmacological, circadian components? After all, it's a jungle out there! And a jungle in here, when you suffer from Wernicke's and are visually impaired.

**Key words:** Electroencephalography, delirium prevention, emergence delirium, emergence agitation, dexmedetomidine, anaesthesia, general

## Introduction

We present the case of 51 year aged patient known for Wernicke's encephalopathy due

## Address for correspondence:

Dr Friedrich Lersch  
Department of Anaesthesiology  
and Pain Medicine, Inselspital,  
Bern University Hospital,  
University of Bern,  
Bern, Switzerland  
Email: lamicrofritz@hotmail.com

## Article History

Received: 30<sup>th</sup> April 2021

Revision: 14<sup>th</sup> May 2021

Accepted: 9<sup>th</sup> June 2021

Published: 30<sup>th</sup> June 2021

**How to cite this article:** Friedrich Lersch, Astrid Kuonen, Fredy Kuonen. Postoperative Delirium averted by EEG-guided opioid-sparing multimodal general anaesthesia. Indian J Ophthal Anaesth 2021;1(2):21-5



to severe and ongoing alcohol dependency of many years. Apart from arterial hypertension and 18 packets cigarette consumption, the patient's history was remarkable for a past motorcycle accident with severe head trauma and complicated fractures of the legs that resulted in multiple surgical procedures. He was undergoing treatment in a pain clinic for his chronic pain connected to the leg's trauma. He had past history of violent bouts of postoperative delirium after surgery which several times aggravated by grand-mal seizures in the context of alcohol deprivation. The patient was scheduled for bilateral cataract surgery of mature cataract. In the premedication clinic, it was clear that undergoing surgery in monitored anaesthesia care (MAC) even in sub-Tenon's block was out of the question due to his uncontrolled movements and exceeding nervousness. General anaesthesia (GA) was scheduled on a day-patient basis. His wife, a retired nurse, stated that she had taken her husband home while being delirious on previous occasions. Returning to his familiar surrounding had always calmed him sufficiently.

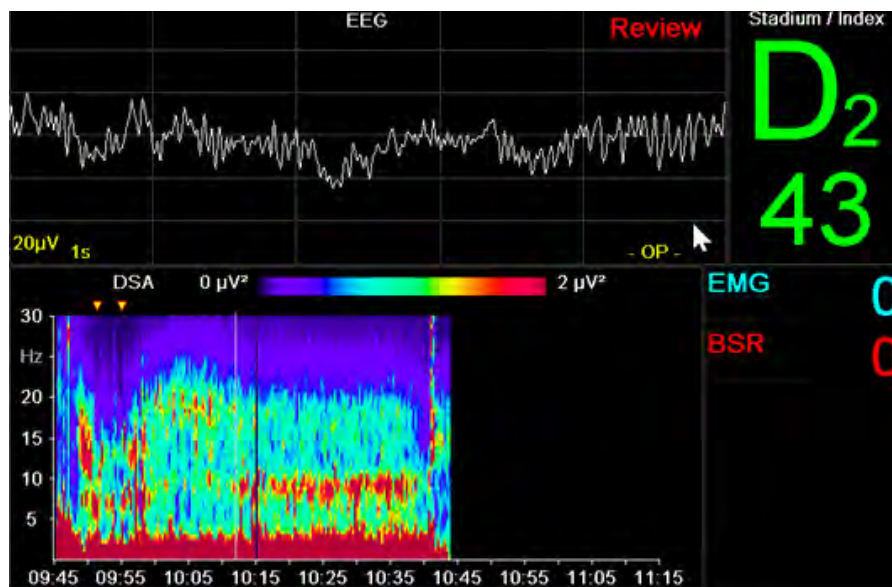
Our patient arrived remarkably anxious in the anaesthesia bay accompanied by his wife after receiving 150 mcg clonidine and 6 mg melatonin as oral premedication on the ward. He restated that his wife's presence kept his anxiety at bay. As he was nil-per-mouth and had abstained from alcoholic beverages and cigarettes overnight, we planned to secure his airway by a laryngeal mask airway. Apart from the standard monitoring, a 3-electrode EEG was mounted

on his forehead and 0.3 mcg/kg bodyweight of dexmedetomidine was injected over 10 minutes. During anaesthesia preparation, his favourite music was played via a mobile loudspeaker and the patient kept holding his wife's hand until induction of anaesthesia was completed. Along with the music, the patient was asked to imagine himself in pleasant scenery and to keep breathing in a deep, relaxing manner. The anxiolytic and euphorising effect of propofol induction was described beforehand as part of anxiolytic communication.

Anaesthesia strategy was outlined to be TIVA with propofol and ketamine along with oxybuprocaine local anaesthesia drops as well as two boluses of intravenous lidocaine of 0.75 mg /kg bodyweight before cataract was operated in each eye. Sub-Tenon's block as add-on to GA was decided as default analgesia, should cataracts prove to be too hard to be extracted via phacoemulsification. It was determined that long stretches of EEG-burst-suppression in GA would be avoided and spontaneous breathing be aimed at under still deep, sleep-like anaesthesia. Consequently, GA was determined to be opioid sparing.

Induction was smooth and airway was secured by LMA without problems. After injecting propofol 110 mg iv via infusion pump (TCI Schneider) as well as alfentanil 500 mcg iv and another bolus of 0.15 mcg/kg bodyweight of dexmedetomidine, EEG (figure 1) showed spindle-rich general anaesthesia. Five minutes before incision Ketamine 50 mg iv was injected (figure 1, EEG below at 09.57) I0061935 and propofol

TIVA was maintained at cet 2.30 mcg/ml. Systemic hypertension under anaesthesia with systolic values at 170 mmHg was successfully treated with 2 boluses of 10 mg urapidil. Ventilation was maintained at 60 % FiO<sub>2</sub>, at 2 litre fresh-gas-flow and pressure support ventilation. Oxygen saturation, sinus rhythm at 60 bpm and average blood pressure at 145/100 mm Hg were in the normal range for the rest of surgery. Surgery of both eyes was lasted for 25 minutes and was uneventful. Once adequate tidal volume was generated at spontaneous breathing, LMA was removed in deep plane of anaesthesia a few minutes after completion of the 2nd eye's phacoemulsification and IOL insertion. Patient was transferred to his bed while still asleep and awoke 30 minutes later in the presence of his wife. He had good recall of all pre-anaesthesia situations and had no signs of delirium. Three hours after termination of GA, he was able to return home with his wife and spent a good afternoon and enjoyed a good sleep at night. Both the patient and his wife expressed astonishment and relieve of the postoperative trajectory to undisturbed cognition:



**Figure 1:** Anaesthesia spindle in raw EEG outlined by red horizontal arrows, mark background alpha activity after propofol-bolus at 9.51 (1st yellow arrowhead) and low beta-activity starting with ketamine bolus at 9.57 (2nd yellow arrowhead). DSA spectrogram illustrates spindle-rich alpha-delta activity from 10.12 until 10.42, followed by smooth emergence to a sleep-like state with faster spindles and EMG-activity in beta range on emergence after 10.42. Red horizontal arrows outline anaesthesia-spindle in the raw-EEG trace.

## Discussion

While short duration and minor invasiveness of the ophthalmic procedure certainly helped in avoiding postoperative delirium, several factors deserve short discussion in this patient with a high pre-surgery probability of postoperative delirium. Monitoring perioperative EEG to avoid oversedation seems to be beneficial<sup>1</sup> although overall benefits are still debated<sup>2</sup>. We believe that especially monitoring for anaesthesia-spindles in the raw EEG<sup>3</sup> together with spectrogram, dexmedetomidine administration and multimodal analgesia<sup>4</sup> help in safeguarding patients at risk. A comparison of different quantitative and processed methods vs gauging anaesthesia-depth from raw perioperative EEG is well beyond the scope of this case vignette. Some relevant literature is outlined in the bibliography.<sup>5,6,7</sup> The role of spindle-rich anaesthesia in reducing postoperative delirium cannot be stressed enough.<sup>3</sup>

A newer strategy that we adopted recently is the premedication with melatonin.<sup>8</sup> Current research opening the field to intravenous use of melatonin<sup>9</sup> may increase our knowledge about beneficial anaesthesia more in the line of the “biomimetic sleep” concept offered by Akeju et al.<sup>10</sup> This might prove especially useful in patients with diminished eye-sight and consequent circadian dysrhythmia predisposing to cognitive complications.<sup>11</sup>

The ketamine signature is easily recognizable in the DSA spectrogram as an upsurge from the alpha-band (9-15 Hz) into the beta-band (> 15 Hz). Ketamine is an integral part of multimodal or opioid-free anaesthesia.<sup>12 13</sup> In this case an opioid-sparing technique (ie dramatically reduced opioid administration) was preferred to an completely opioid-free anaesthesia (OFA). Using small boluses of alfentanil reduce brainstem reactions like gagging or coughing on securing the airway. Applying OFA to eye-surgery patient with tracheal intubation again is a wide-ranging discussion for the very reason of brainstem reactions to a tracheal tube can be detrimental to the operated eye. As for the atypical systemic hypertension under sufficient propofol GA, measures were taken to bring systemic pressure back to normal, as choroidal bleeding has been reported in phacoemulsification.<sup>14</sup> The main pathophysiological mechanism to be understood by anaesthesiologists in this context is an increase in transmural pressures of the choroidal vessels.<sup>15</sup> The main difference between dexmedetomidine-dominant multimodal anaesthesia with most other forms of GA is a prolonged sleepiness of the patients. This proves to be a challenge

for the anaesthetists as often sleepiness is interpreted as “abnormal”. A look at the EEG during anaesthesia could easily prove this perception wrong in most cases. NREM-like sleep activity in the post-operative phase seems to lie at the heart of reduced emergence delirium and postoperative delirium observed in dexmedetomidine-treated patients.<sup>1617</sup>

In a clinical environment known for the high incidence of sleep-deprivation and consecutive delirium this might prove an example of “healing sleep”.<sup>1810</sup>

Lastly, the adoption of non-pharmacological elements of anxiolysis before induction (presence of a loved-one, calming music of own choice, imagined scenery, calm breathing etc) is little discussed in ophthalmic anaesthesia but is repeatedly cited as beneficial by literature and patients alike.<sup>192021</sup>

## References:

1. Fritz BA, Kalarickal PL, Maybrier HR, et al. Intraoperative Electroencephalogram Suppression Predicts Postoperative Delirium. *Anesth Analg* 2016;122:234-42
2. Wildes TS, Mickle AM, Avidan MS. Electroencephalography-Guided Anesthetic Administration and Postoperative Delirium -Reply. *JAMA* - 2019;321:2471-2
3. Hesse S, Kreuzer M, Hight D, et al. Association of electroencephalogram trajectories during emergence from anaesthesia with delirium in the postanesthesia care unit: an early sign of postoperative complications. *Br J Anaesth* 2019;122:622-34

4. Jin Z, Hu J, Ma D. Postoperative delirium: perioperative assessment, risk reduction, and management. *Br J Anaesth.* 2020;125:492-504
5. Marchant N, Sanders R, Sleight J, et al. How electroencephalography serves the anesthesiologist. *Clin EEG Neurosci* 2014; 45:22-32
6. Bennett C, Voss LJ, Barnard JPM, Sleight JW. Practical use of the raw electroencephalogram waveform during general anesthesia: The art and science. *Anesth Analg* 2009;109:539-50
7. Palanca BJA, Mashour GA, Avidan MS. Processed electroencephalogram in depth of anesthesia monitoring. *Curr Opin Anaesthesiol.* 2009;22:553-9
8. Campbell AM, Axon DR, Martin JR, Slack MK, Mollon L, Lee JK. Melatonin for the prevention of postoperative delirium in older adults: A systematic review and meta-analysis. *BMC Geriatr* 2019;19:272
9. Andersen LPH, Werner MU, Rosenkilde MM, et al. Pharmacokinetics of oral and intravenous melatonin in healthy volunteers. *BMC Pharmacol Toxicol* 2016; 17:8
10. Akeju O, Hobbs LE, Gao L, et al. Dexmedetomidine promotes biomimetic non-rapid eye movement stage 3 sleep in humans: A pilot study. *Clin Neurophysiol* 2018; 129: 69–78
11. Tan C, Saito N, Miyawaki I, Shiotani H. Preoperative circadian physical activity rhythm and postoperative delirium in cardiovascular surgery patients. *Chronobiol Int* 2020; 37:1059-66
12. Mulier J, Dekock M. Opioid free general anesthesia, a new paradigm? *Best Pract Res Clin Anaesthesiol.* 2017;31:441-3.
13. Brown EN, Pavone KJ, Naranjo M. Special Article: Multimodal General Anesthesia: Theory and Practice. *Anesth Analg* 2018; 127: 1246-58
14. Savastano A, Rizzo S, Savastano MC, et al. Choroidal effusion and suprachoroidal hemorrhage during phacoemulsification: Intraoperative management to prevent expulsive hemorrhage. *Eur J Ophthalmol* 2016;26:338-41
15. Bellows AR, Chylack LT, Hutchinson BT. Choroidal Detachment: Clinical Manifestation, Therapy and Mechanism of Formation. *Ophthalmology* 1981;88:1107-15
16. Janssen TL, Alberts AR, Hooft L, Mattace-Raso FUS, Mosk CA, Van Der Laan L. Prevention of postoperative delirium in elderly patients planned for elective surgery: Systematic review and meta-analysis. *Clin Interv Aging.* 2019;14:1095-1117
17. Palanca BJA, Wildes TS, Ju YS, Ching S, Avidan MS. Electroencephalography and delirium in the postoperative period. *Br J Anaesth* 2017;119:294-307.
18. Wang Y, Shen X. Postoperative delirium in the elderly: the potential neuropathogenesis. *Aging Clin Exp Res* 2018;30:1287-95
19. Cruise CJ, Chung F, Yogendran S, Little D. Music increases satisfaction in elderly outpatients undergoing cataract surgery. *Can J Anaesth* 1997;44: 43-8
20. Agard E, Pernod C, El Chehab H, Russo A, Haxaire M, Dot C. A role for hypnosis in cataract surgery: Report of 171 procedures. *J Fr Ophtalmol* 2016;39:287-91
21. Chundamala J, Wright JG, Kemp SM. An evidence-based review of parental presence during anesthesia induction and parent/child anxiety. *Can J Anesth.* 2009; 56:57-70.



## A child with Moebius syndrome for squint surgery: Anaesthetic management and literature review

Ankur Sharma<sup>1</sup>, Varuna Vyas<sup>2</sup>, Renu Sinha<sup>3</sup>

<sup>1</sup>Associate Professor, Department of Trauma & Emergency (Anesthesiology), All India Institute of Medical Sciences (AIIMS), Jodhpur, Rajasthan, <sup>2</sup>Associate Professor, Department of Pediatrics, All India Institute of Medical Sciences (AIIMS), Jodhpur, Rajasthan, <sup>3</sup>Professor, Department of Anaesthesiology, Pain Medicine & Critical Care, All India Institute of Medical Sciences (AIIMS), New Delhi

### ABSTRACT

Moebius syndrome is an uncommon clinical disease characterised by unilateral or bilateral facial paralysis and abnormal extraocular eye movements. It is caused by congenital paresis of the facial (VII) and abducens (VI) cranial nerves and other genetic abnormalities affecting different bodily systems. We describe a child with Moebius syndrome who had undergone squint surgery under general anaesthesia and the anaesthetic issues it entailed.

**Keywords:** Moebius syndrome, general anaesthesia, squint surgery, airway

### Address for correspondence:

Dr Ankur Sharma  
Associate Professor,  
Department of Trauma &  
Emergency (Anesthesiology),  
All India Institute of Medical Sciences,  
Basni Phase-2, Jodhpur,  
Rajasthan (342005) India  
Mobile No. 09654045653  
Email ID: ankuranaesthesia@gmail.com

### Article History

Received: 15<sup>th</sup> May 2021

Revision: 20<sup>th</sup> May 2021

Accepted: 16<sup>th</sup> June 2021

Published: 30<sup>th</sup> June 2021

### Introduction

Moebius syndrome (MS) is a congenital paralysis of the facial (VII) and abducens (VI) cranial nerves that results in unilateral or bilateral facial paralysis and abnormal extraocular eye movements.<sup>1</sup> The syndrome's characteristic symptoms are often accompanied by hypoglossal (XII), trigeminal (V), glossopharyngeal (IX), and vagal (X) nerve palsies. Children affected by this condition usually have congenital esotropia and expressionless facies.<sup>1</sup> Clinical manifestations vary according to the pattern of cranial nerve involvement. Additionally, Moebius syndrome may occur in conjunction with a variety of other disorders. Mandibular hypoplasia may predispose the patient to have a problematic airway.<sup>2</sup>

These patients may require imaging and surgical interventions to correct eye anomalies (strabismus surgery, ptosis repair, tarsorrhaphy), orthopaedic issues (correction of limb abnormalities), plastic/reconstructive (cleft palate, jaw surgery, facial reanimation surgery), otolaryngological, dental (teeth extractions), or general surgical interventions.<sup>3</sup>

**How to cite this article:** Ankur Sharma, Varuna Vyas, Renu Sinha. A child with Moebius syndrome for squint surgery: Anaesthetic management and literature review. Indian J Ophthal Anaesth 2021;1(2):26-30

The purpose of this article is to describe a child with diagnosed MS who had undergone squint surgery (MR Recess) under general anaesthesia and the anaesthetic complications that might be ensued.

### Case report

A two-year-old male infant weighing 10 kgs came to the ophthalmology outpatient clinic with bilateral inward deviation of the eyes, and left eye lagophthalmos. He exhibited microstomia, drooping of the angle of the mouth (L > R), and mask-like facial characteristics and was thus referred for genetic evaluation, after which MS was identified. His mother was diagnosed with polyhydramnios during the pregnancy. Otherwise, his birth and growth history were normal. The child had bilateral sixth nerve palsy, left seventh nerve palsy, and left median entropion of the upper lid at the time of evaluation (figure 1).



**Figure 1:** Moebius syndrome : Bilateral inward deviation of the eyes, left entropion of the upper lid and slight inclination of the head to the right

While walking, there was a slight inclination of the head to the right. There were no abnormalities seen in the airway. The cervical spine's X-ray revealed a widening of the interscapular distance. All biochemical analyses were within normal ranges. The systematic investigation revealed no anomalies.

During the preoperative evaluation, informed written permission was acquired from the child's parents.

All standard monitors (ECG, pulse oximetry, and NIBP) were attached in the operating room. We used incremental dosages of 5-8% sevoflurane in combination with oxygen and nitrous oxide for inhalational induction. Following induction, a 24 gauge cannula was secured in the left hand. Intravenous atracurium 2 mg and fentanyl 15 µg were administered when adequate mask ventilation was achieved, and the airway was maintained with a size 1.5 air-Q™ intubating laryngeal airway (ILA) (Cookgas LLC, Mercury Medical, Clearwater, FL, USA). Isoflurane and nitrous oxide at 50% O<sub>2</sub> were used to maintain anaesthesia. Intravenous ondansetron 1.0 mg was given for postoperative nausea and vomiting prevention. At the conclusion of the operation, neuromuscular blockade was reversed by using 500 µg neostigmine and 100 µg glycopyrrolate intravenously. Once the child was completely awake, the Air-Q was removed. The patient's recovery and postoperative period were uneventful.

### Discussion

While Von Graefe reported a case of congenital facial diplegia in 1880, Paul Julius Möbius, a German neurologist, investigated and characterised the condition further in 1888. It occurs at a rate of 0.002% of births, or one in every 50,000 live births.<sup>1</sup>

Moebius syndrome has a complex aetiology. Two major causative theories for MS include rhombencephalic maldevelopment and brainstem ischemia during the first trimester.<sup>2</sup>

Additionally, hyperthermia, trauma, thrombus formation, embolism, bleeding, and in utero exposure to certain medicines, including misoprostol, are teratogenic. Moebius sequence inheritance is complex and may be autosomal recessive, autosomal dominant, or even X-linked. Although many potential areas and genes (3q21-q22 and 13q12.2-q13) have been reported, no causal gene has been identified to date.<sup>1</sup> Poland-Mobius syndrome is a rare congenital disease characterised by a combination of Poland and Mobius characteristics. Poland syndrome is characterised by the absence of the pectoralis major muscle, syndactyly, brachydactyly, and hand hypoplasia.<sup>1-3</sup>

These individuals may have micrognathia, mandibular hypoplasia, cleft palate, and temporomandibular joint dysfunction.<sup>3</sup> All of these characteristics may make the bag and mask ventilation, intubation, and supra glottic airway device (SGA) placement problematic. We selected air-Q ILA for airway management in our patient because this SGA allows blind and fiberoptic guided intubation if required. If feasible, a thorough airway examination using indirect laryngoscopy should be performed in advance to map any upper airway abnormality. Oculocardiac reflex (OCR) is more common following extraocular muscle manipulation during squint surgery. MS is linked with the involvement of many organ systems. These issues, as well as their related anaesthetic problems,<sup>1-7</sup> have been summarised in Table-1.

Our patient had no problem with mask ventilation or insertion of the air-Q ILA. Ames et al examined 111 anaesthetic records

from 46 MS patients who had undergone various surgical procedures.<sup>8</sup> They found that face mask ventilation was easy in all patients, whereas tracheal intubation was uneventful in 76 cases (71.6% of all intubations). External laryngeal manipulation alone was needed in 17 (16%) cases to improve the view with laryngoscopy. In ten (9.4 per cent) cases, a combination of procedures was required, including cricoid pressure, stylet use, two person method, and blade replacement. Three patients needed fiberoptic intubation. Five patients' surgeries were postponed owing to unsuccessful intubation. Telich-Tarriba et al similarly examined 51 individuals with MS who underwent 172 procedures.<sup>9</sup> They identified four individuals (7%) with a difficult airway. Endotracheal intubation was successful in all patients; 38 patients were intubated successfully on the first attempt, while the other patients required a second effort. Rasmussen et al described a 23-year-old man with MS who died due to difficulties during intubation and sudden circulatory collapse.<sup>10</sup>

## Conclusion

MS may be associated with difficulties with the airway and other anaesthesia-related aspects. It is critical to be aware of these comorbidities, since it may result in unexpected complications during anaesthesia, if left undiagnosed.

## Financial support and sponsorship

Nil.

## Conflicts of interest

There are no conflicts of interest.

**Table-1: The involvement of different organ systems and its anaesthetic implications in a patient with Moebius Syndrome<sup>1,3,4-7</sup>**

Organ involvement	Characteristic findings	Anaesthetic concerns and their management
<b>Airway</b>	Temporomandibular joint dysfunction Cleft palate Congenital bilateral vocal cord paralysis <sup>4</sup> Retention of oral secretions Nasal regurgitation	Difficult airway equipment should be available. Aspiration of oral secretions-antisialogogue premedication Non-opioid analgesics should be used preferentially. Postoperatively extended respiratory monitoring may be required
<b>Face</b>	Expressionless (Mask) facies Broad root of the nose Mandibular hypoplasia Microstomia Microglossia Micrognathia Hypertelorism	Difficult to measure and assess pain. The degree of analgesia should be determined by changes in physiological markers (heart rate and blood pressure). Difficulty in bag and mask ventilation
<b>Musculoskeletal deformity</b>	Club foot Smallness of limbs Syndactyly Brachydactyly Missing fingers or toes Arthrogryposis multiplex congenita Klippel-Feil anomaly Poland sequence (I/L abnormalities of the hands and a full or partial absence of the pectoralis muscles and breast) association with 15% of patients Webbing of axilla	Difficulty in positioning on OT table Avoid succinylcholine due to the danger of rhabdomyolysis, hyperkalemia, and malignant hyperthermia <sup>5</sup> Difficulty in securing intravenous access
<b>Neurological and skull</b>	Paresis of the facial, abducens, hypoglossal, trigeminal, glossopharyngeal and vagal nerve Seizure disorders Hypotonia, Hydrosyringomyelia <sup>6</sup> Holoprosencephaly <sup>7</sup> Autism Speech problems Mental retardation (Rare)	Train-of-four monitoring due to hypotonia Hypoglossia or ankyloglossia combined with poor tongue coordination increases the risk of secretion.
<b>Eye and Ear</b>	<b>Eye-</b> Congenital esotropia, incomplete eye closure, ptosis, conjunctivitis, corneal opacities, ophthalmoplegia, epicanthus, lateral gaze paralysis <b>Ear-</b> External ear deformities, otitis media	Exposure keratopathy Oculocardiac reflex (OCR) and postoperative nausea and vomiting (PONV) are more common after squint surgery. Communication difficulties with child
<b>Cardiovascular</b>	Congenital heart diseases (ventricular septal defect, patent ductus arteriosus, dextrocardia)	Preoperative echocardiography, Anaesthetic considerations based on the cardiac lesion
<b>Miscellaneous</b>	Dysphagia Dysarthria Hypogonadotropic hypogonadism Prematurity Café-au-lait pigmentation	Feeding problems as a result of inadequate sucking and swallowing



## References

1. Picciolini O, Porro M, Cattaneo E, Castelletti S, Masera G, Mosca F et al. Moebius syndrome: clinical features, diagnosis, management and early intervention. *Ital J Pediatr.* 2016;42:56.
2. Budić I, Šurdilović D, Slavković A, Marjanović V, Stević M, Simić D. Moebius syndrome: challenges of airway management. *Acta Clin Croat.* 2016;55 Suppl 1:94-7.
3. Gondipalli P, Tobias JD. Anaesthetic implications of Möbius syndrome. *J Clin Anesth.* 2006;18:55-9.
4. Kanemoto N, Kanemoto K, Kamoda T, Hasegawa M, Arinami T. A case of Moebius syndrome presenting with congenital bilateral vocal cord paralysis. *Eur J Pediatr.* 2007;166:831-3.
5. Fernandes CR, Pinto Filho WA, Cezar LC, Alves Gomes JM, Florencio da Cunha GK. Fatal recrudescence of malignant hyperthermia in an infant with Moebius syndrome. *Braz J Anesthesiol.* 2013;63:296-300.
6. Losito L, Gennaro L, Cacudi M, De Rinaldis M, Trabacca A. Moebius syndrome and hydrosyringomyelia: description of a new association. *J Child Neurol.* 2013;28:801-4.
7. Pirmez R, Freitas ME, Gasparetto EL, Araújo AP. Moebius syndrome and holoprosencephaly following exposure to misoprostol. *Pediatr Neurol.* 2010;43:371-3.
8. Ames WA, Shichor TM, Speakman M, Zuker RM, McCaul C. Anesthetic management of children with Moebius sequence. *Can J Anaesth.* 2005;52:837-44.
9. Telich-Tarriba JE, Guevara-Valmaña O, Ruiz-Beltran S, Aguiar-Rosas S, Cardenas-Mejia A. Difficult Airway Identification and Management in Patients With Moebius Syndrome. *J Craniofac Surg.* 2020;31:183-5.
10. Rasmussen LK, Rian O, Korshøj AR, Christensen S. Fatal Complications During Anaesthesia in Moebius Syndrome: A Case Report and Brief Discussion of Relevant Precautions and Preoperative Assessments. *Int J Anesth Res.* 2015;3: 116-8.



**Next IJOA issue will be released on-line on Jan 2022.**

**I Kindly request the members to submit article (Original article / Case report / Brief communication/ Letters) to [editorijoa@gmail.com](mailto:editorijoa@gmail.com)**

**Dr Renu Sinha**  
Editor, Indian Journal of Ophthalmic Anaesthesia, IJOA

## Retrobulbar Neurolytic Block with Alcohol for Eye Pain: Experience in 12 Patients and Review of the Literature

Oya Yalcin Cok<sup>1</sup>

<sup>1</sup>Baskent University, School of Medicine, Department of Anaesthesiology and Reanimation, Pain Clinic, Ankara, TURKEY

### ABSTRACT

Eye pain may be mild to severe, difficult to treat condition with various underlying causes. The modalities for the management of painful eye includes medical treatment, neurolysis and surgical interventions such as evisceration and enucleation. Chemical neurolysis for eye pain is provided by the injection of neurolytic chemical agents such as alcohol, phenol, and chlorpromazine by retrobulbar block technique. Here, we aimed to review the practice of retrobulbar neurolytic block with alcohol for eye pain and share our experience in 12 patients.

**Keywords:** Eye pain, retrobulbar block, alcohol

### INTRODUCTION

Eye pain, mostly reserved in the ocular area, is a type of ophthalmic pain syndrome. It may be mild to severe with various underlying causes.<sup>1-3</sup> The etiology of ocular

pain may include but not limited to corneal diseases, orbital tumors, posterior scleritis, optic neuropathy, orbital myositis, phantom eye syndrome and mostly trauma.<sup>4</sup> The affected eye may be blind or seeing. The character of the eye pain may be described as stabbing, pulsating, throbbing, cutting, penetrating, radiating, shooting or superficial burning.<sup>5</sup> However, it is often difficult to describe for the patient and to treat for the clinician.

The modalities for the management of painful eye include medical treatment, neurolysis and surgical interventions such as evisceration and enucleation.<sup>6,7</sup> Neurolysis stands as a bridging option when the medical therapy is insufficient to treat the pain and when the patient isn't physically or psychologically fit for amputation of the eye. Neurolysis is the destruction or disintegration of a nerve tissue by either of the techniques such as chemical agent injection, cryoablation, radiofrequency lesioning and neurosurgery. Chemical neurolysis for eye pain is provided by the injection of neurolytic chemical agents such as alcohol, phenol, and chlorpromazine by retrobulbar block technique.

Here, we aimed to review the practice of retrobulbar neurolytic block with alcohol for

### Address for correspondence:

Dr Oya Yalcin Cok  
Professor, Adana Dr Turgut  
Noyan Research and Education Center  
Dadaloglu M, 2159 S 4/A  
01250, Yuregir, Adana, TURKEY  
Email ID: oyacok@yahoo.com

### Article History

Received: 15<sup>th</sup> May 2021

Revision: 25<sup>th</sup> May 2021

Accepted: 18<sup>th</sup> June 2021

Published: 30<sup>th</sup> June 2021

**How to cite this article:** Oya Yalcin Cok. Retrobulbar Neurolytic Block with Alcohol for Eye Pain: Experience in 12 Patients and Review of the Literature. Indian J Ophthal Anaesth 2021;1(2):31-7

eye pain and share our experience in 12 patients.

## CASES

All patients were referred from ophthalmology department. They had chronic eye pain that was non-responding to medications as well as they weren't medically or psychologically fit for enucleation or evisceration. All patients had thorough ophthalmic examination prior to referral to pain clinic to identify possible difficult or contraindicated eyes for retrobulbar injection with such features as staphyloma, previous buckling, long axial length, myopic eyes, big or small, deep or shallow orbit, infection. The examination of pain included the identification of pain site, pain type and severity, previous medications and interventions. Severity of pain was recorded according to numeric rating scale (NRS) where 0 was "no pain" and 10 was "the worst imaginable pain".

The patients were adults except one patient who was 12 years old. Gender distribution was homogenous. The major cause of eye pain was neovascular glaucoma. NRS scores for pain was between 7 and 10. They were all on antiglaucoma medication and received pain medications such as opioids, NSAIDs, paracetamol and pregabalin. Table 1. demonstrates the demographic data and ophthalmological background of the patients.

All patients gave informed consent for the procedure after receiving related information on the intervention, possible benefits and complications. The site of the pain and intervention was triple-checked before the procedure. The patients had standard monitoring with

electrocardiography, pulse oximetry, non-invasive blood pressure assessment and intravenous access. All blocks were performed by the same pain physician (OYC) in an operating room where resuscitation equipment was readily available. Patients received no sedative premedication. The equipment for retrobulbar alcohol injection was prepared considering the sterilization regulations of the institute (Figure 1).

Topical anaesthesia of the eye with proparacaine HCl 0.5% was followed by regional asepsis with betadine diluted with saline to 5% to protect cornea. Subcutaneous local anaesthesia was obtained by 0.2% lidocaine with a 26 G, 13 mm needle (Shandong Qiao Pai Group Co. Ltd, PRC) at inferotemporal quadrant for retrobulbar needle introduction (Figure 2a). Then, the retrobulbar block was performed with 2 mL lidocaine 2% and a 25 G, 3.8 cm needle (Code no 0120, Sterimedix, Redditch, UK) was inserted percutaneously at the junction of inferior and lateral margins of orbit (Figure 2b). Then the syringe was disconnected but the needle left in place for 5 minutes to ensure block success and adequate analgesia prior to injection of 2 mL absolute alcohol (96%) (Figure 2c). After the block, an ice pack was placed on the lid for an hour to decrease the oedema formation. The patients were discharged home after being observed for 2 hours on the same day with their regular anti-glaucoma medications.

All patients had a pain relief for various durations for 2 months up to 26 months. Their NRS scores were between 0 and 2 after retrobulbar alcohol injection. All remained on antiglaucoma medications, but rarely on analgesics.

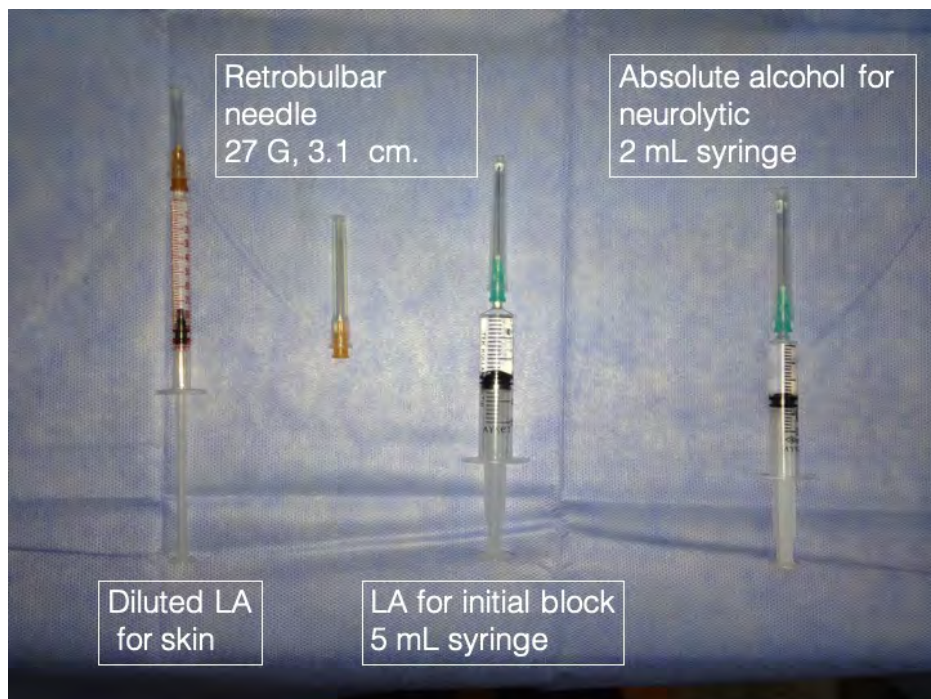


**Table 1. Patients' demographics**

Case	Age (yrs)	Gender	Diagnosis	Medications	NRS
1	46	Female	Neovascular glaucoma	Antiglaucoma, opioids	8
2	55	Female	Neovascular glaucoma	Antiglaucoma, opioids, pregabalin	9
3	57	Male	Neovascular glaucoma	Antiglaucoma, pregabalin	8
4	78	Female	Neovascular glaucoma	Antiglaucoma, opioids, paracetamol, pregabalin	7
5	82	Female	Neovascular glaucoma	Antiglaucoma drugs, paracetamol	7
6	58	Male	Absolute glaucoma	Antiglaucoma, NSAID, opioids	8
7	80	Male	Absolute glaucoma	Antiglaucoma, pregabalin	9
8	71	Female	Absolute glaucoma, phthisis bulbi	Antiglaucoma, paracetamol, opioids	9
9	55	Male	Neovascular glaucoma	Antiglaucoma, opioids, NSAID, pregabalin	10
10	67	Female	Absolute glaucoma, phthisis bulbi	Antiglaucoma, opioids, pregabalin	9
11	59	Male	Neovascular glaucoma	Antiglaucoma, opioids, NSAID, paracetamol, pregabalin	9
12	12	Male	Congenitally blind eye Vitreous haemorrhage, increased IOP	Antiglaucoma, paracetamol, NSAID	8

NRS: Numeric rating scores for pain (0=no pain, 10= the worst imaginable pain)

NSAID: Non-steroidal anti-inflammatory drugs

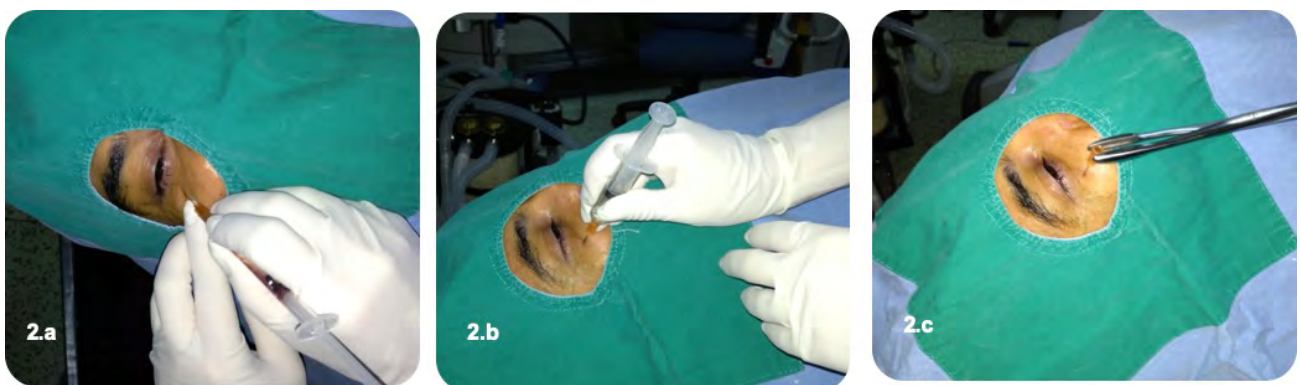


**Figure 1. Retrobulbar alcohol injection preparation**



**Table 2. Patient and pain outcomes of the retrobulbar alcohol injection**

Case	Duration of pain relief	Complications	Current Status	
			NRS	Medications and interventions for pain
1	24 months	Eye lid edema	2	NSAID
2	18 months	Eye lid edema, chemosis	1	None
3	13 months	Eye lid edema, transient blepharoptosis	2	None
4	10 months,	Eye lid edema, chemosis	0	None until the repeat block at 12th month
5	26 months	Eye lid edema	0	None Died of other causes
6	6 months	Eye lid edema, chemosis	1	None
7	5 months	Eye lid edema, chemosis	1	None
8	9 months	Eye lid edema	1	None until repeat block at 9th month
9	21 months	Eye lid edema, chemosis	2	NSAIDs
10	2 months	Eye lid edema, chemosis	2	Bacterial corneal ulcer, corneal melt, evisceration
11	10 month	Eye lid edema	1	None
12	5 months	Eye lid edema	2	Enucleation due to increased haemorrhage



**Figure 2. Retrobulbar alcohol injection**

Two of the patients needed repeat injections. Two patients required surgical intervention due to ophthalmological factors. One died of natural causes during the follow-up. Patient and pain outcomes of the retrobulbar alcohol injection were shown in Table 2.

## DISCUSSION

Eye pain has mostly been managed by different specialties of medicine such as ophthalmology, neurology and pain medicine. These specialties use various treatment options including medical and surgical modalities as well as neurolytic interventions. Medical treatment for eye pain may target the etiological factors with medications such as antiglaucoma drugs or may manage the somatic and neuropathic symptoms according to World Health Organization Analgesic ladder with paracetamol, non-steroidal anti-inflammatory drugs, opioids, antidepressants and anticonvulsants.<sup>8</sup> Surgical interventions' success rates have been between 70 and 90%, however they also carry risks. Enucleation has the higher pain relief up to 93%. But it is not well-accepted and consented by the patients, and not very suitable in most of malignant cases. Although evisceration is a simpler procedure, its efficacy for ocular pain is less due to remaining intact sensory ciliary nerves.

Neurolytic blocks for ocular pain may only be performed by retrobulbar technique. Peribulbar and sub-Tenon approach aren't feasible for injection of a neurolytic agent such as alcohol, phenol, and chlorpromazine. Retrobulbar block, which was first described by Atkinson<sup>9</sup> in 1936, with a long needle

(3.8 cm) introduced to intraconal space, has evolved into a modern technique with a shorter needle, a more inferolateral site of injection and neutral gaze during the block. Retrobulbar block, theoretically, affects all nerves in the intraconal space such as all motor nerves except the trochlear nerve, nasociliary or nasal nerve, long and short ciliary nerves, ciliary ganglion, optic nerve. This also applies to retrobulbar alcohol injection which may lead to loss of muscle functions and vision while providing pain relief. For this reason, retrobulbar alcohol (and phenol) injection has rarely been recommended for pain in seeing eyes, but mostly reserved for blind eyes. However, there are papers advocating chlorpromazine use for retrobulbar injection in seeing eyes.<sup>10,11</sup>

Alcohol used for retrobulbar block must be at a concentration of 95% or above to provide neurolysis. It precipitates mucoprotein and lipoprotein and extracts phospholipids, cholesterol and cerebroside from neural tissues.<sup>12</sup> Its affinity to vascular tissue is less in comparison to phenol. Twelve to 24 hours is required before the assessment of its effect. Retrobulbar local anaesthetic injection and a few minutes for it to take an action is essential prior to alcohol administration because sole alcohol injection causes a severe burning pain along the nerve trajectory during the procedure. Alcohol also spreads rapidly in the surrounding connective tissue leading to excessive oedema on the upper and lower lid and temporary blepharoptosis in many patients. The other agent-related complications include chemosis, cellulitis, corneal ulcer, orbital inflammation and loss of sensation in the surrounding region.<sup>13,14</sup> Furthermore, technical complications such

as retrobulbar haemorrhage, globe penetration or perforation, optic nerve injury, and subarachnoid injection can be observed with various incidence rates during retrobulbar block.<sup>15,16</sup> Possible nerve regeneration affects the outcomes such as unpredictable duration of pain relief and reoccurrence of pain.

The use of alcohol for retrobulbar block has first reported in 1949 by Kornblueth and Maumenee.<sup>17,18</sup> Although retrobulbar alcohol injection has lost its popularity in the last three decades, this intervention reported to have a success rate up to 100% with a pain relief duration of 2 weeks to 2 years even in difficult circumstances such as presence of malignancy and even after enucleation.<sup>19-21</sup> Recent papers remind its place in the armamentarium of the pain physicians.<sup>22</sup> Retrobulbar alcohol injection has been reported to be as effective as chlorpromazine for neurolysis regarding success rate of the block and the decrease in intraocular pressure, but transient eye lid oedema was more frequent following the alcohol administration.<sup>23</sup>

In our case series, the outcomes and the complications resembled the findings of previous studies and case reports regarding the etiology of the pain, pain severity and type, duration of pain relief, follow-up medications and need for a repeat block. We treated patients with severe pain, mostly due to neurovascular glaucoma, with retrobulbar alcohol injection, and the most prominent complication was eye lid oedema and the pain relief lasted approximately for 14 months.

In conclusion, the use of retrobulbar neurolytic blocks is established in the management of ophthalmic pain, and alcohol is an effective agent for chemical neurolysis. The main objective for performing retrobulbar alcohol injection should be the selection of appropriate patients and careful block performance considering possible benefits and complications.

### **Financial support and sponsorship**

Nil.

### **Conflicts of interest**

There are no conflicts of interest.

### **REFERENCES**

1. Melik Parsadaniantz S, Rostène W, Baudouin C, Réaux-Le Goazigo A. Vers une meilleure compréhension des douleurs oculaires chroniques [Understanding chronic ocular pain]. *Biol Aujourd'hui*. 2018;212:1-11.
2. Rasmussen ML, Prause JU, Toft PB. Phantom pain after eye amputation. *Acta Ophthalmol*. 2011;89:10-6.
3. Rosenthal P, Borsook D, Moulton EA. Oculofacial Pain: Corneal Nerve Damage Leading to Pain Beyond the Eye. *Invest Ophthalmol Vis Sci*. 2016 Oct 1;57(13):5285-7
4. Kulenkamp J, McClelland CM, Lee MS. Eye pain in the white and quiet eye. *Curr Opin Ophthalmol*. 2020;31:483-8.
5. Moshirfar M, Benstead EE, Sorrentino PM, Tripathy K. Ocular Neuropathic Pain. 2021 Feb 14. In: StatPearls [Internet]. Treasure Island (FL): StatPearls Publishing; 2021 Jan.

6. Sloan PA, Kancharla A. Treatment of neuropathic orbital pain with gabapentin. *J Pain Palliat Care Pharmacother*. 2003;17:89-94.
7. Kavalieratos CS, Dimou T. Gabapentin therapy for painful, blind glaucomatous eye: case report. *Pain Med*. 2008;9:377-8.
8. Starr MR, Patel LG, Ammar M, Yonekawa Y. Opioids and ophthalmology: review of the current literature. *Curr Opin Ophthalmol*. 2021;32:209-13.
9. Atkinson WS. *Trans Am Ophthalmol Soc* 1934;32:399-451
10. Estafanous MF, Kaiser PK, Baerveldt G. Retrobulbar chlorpromazine in blind and seeing painful eyes. *Retina*. 2000;20(5):555-8.
11. Chen TC, Ahn Yuen SJ, Sangalang MA, Fernando RE, Leuenberger EU. Retrobulbar chlorpromazine injections for the management of blind and seeing painful eyes. *J Glaucoma*. 2002;11:209-13.
12. Dua HS, Deshmukh R, Ting DSJ, Wilde C, Nubile M, Mastropasqua L, Said DG. Topical use of alcohol in ophthalmology - Diagnostic and therapeutic indications. *Ocul Surf*. 2021;21:1-15.
13. Pham Dang N, Zitte K, Bonnin N, Delbet-Dupas C, Barthélémy I. Aseptic serous cellulitis of the right hemiface following a retrobulbar alcohol injection. *J Fr Ophtalmol*. 2016;39:e33-5.
14. Eftekhari K, Shindler KS, Lee V, Dine K, Eckstein LA, Vagefi MR. Histologic Evidence of Orbital Inflammation from Retrobulbar Alcohol and Chlorpromazine Injection: A Clinicopathologic Study in Human & Rat Orbits. *Ophthalmic Plast Reconstr Surg*. 2016;32:302-4.
15. Kumar CM, Dowd TC. Complications of ophthalmic regional blocks: their treatment and prevention. *Ophthalmologica*. 2006;220:73-82.
16. Morgan CM, Schatz H, Vine AK, Cantrill HL, Davidorf FH, Gitter KA, Rudich R. Ocular complications associated with retrobulbar injections. *Ophthalmology*. 1988;95:660-5.
17. Kornblueth W. The effect of retrobulbar alcohol injection on the eyes of experimental animals. *Am J Ophthalmol* 1949;32:781-92
18. Maumenee AE. Retrobulbar alcohol injections; relief of ocular pain in eyes with and without vision. *Am J Ophthalmol* 1949;32:1502-8
19. Çok OY, Eker HE, Cantürk S, Yaycioğlu R, Ariboğan A, Arslan G. Pain management in blind, painful eyes: clinical experience with retrobulbar alcohol injection in 4 cases. *Agri*. 2011;23:43-6.
20. Kumar CM, Dowd TC, Hawthorne M. Retrobulbar injection for orbital pain relief under difficult circumstances: a case report. *Ann Acad Med Singapore* 2006;35:260-5
21. Jaichandran VV, Bhaskar S. Retrobulbar alcohol injection for phantom eye pain syndrome in bilateral eviscerated orbit. *Oman J Ophthalmol*. 2017;10:264-5.
22. Akhtar N, Tayyab A, Kausar A, Jaffar S. Pain management with retrobulbar alcohol injection in absolute glaucoma. *J Pak Med Assoc*. 2015;65:678-80.
23. Galindo-Ferreiro A, Akaishi P, Cruz A, Khandekar R, Al Dosairi S, Dufailej M, Al Salem A, Galvez-Ruiz A, Craven ER. Retrobulbar Injections for Blind Painful Eyes: A Comparative Study of Retrobulbar Alcohol Versus Chlorpromazine. *J Glaucoma*. 2016;25:886-90.



## Peribulbar block - Pros Vs Cons: A debate

*Jaichandran V V<sup>1</sup>, Keith Allman<sup>2</sup>*

<sup>1</sup>Department of Anaesthesiology, Sankara Nethralaya, Chennai, India,

<sup>2</sup>Consultant Anaesthetist, Royal Devon and Exeter NHS Foundation Trust, Exeter, UK.

### Introduction

Regional anaesthesia in cataract surgery ranges from akinetic blocks involving a needle<sup>1,2</sup> to non-akinetic topical anaesthesia techniques.<sup>3</sup> Following the introduction of foldable intraocular lens and with lesser surgical manipulation, subtenon block (STB) and topical anaesthesia were found to be sufficient for performing cataract surgery. In countries like United States and United Kingdom, surveys have reported a decline in the use of retrobulbar and peribulbar block (PBB), with STB and topical techniques gaining popularity.<sup>4,5</sup> On the other hand, in a recent cross-sectional survey done among the Ophthalmology trainees in a tertiary ophthalmic centre in India, it was found that nearly 92% preferred sharp needle blocks over STB or topical anaesthesia for performing cataract surgery.<sup>6</sup>

### Address for correspondence:

Dr Jaichandran V V

Deputy Director, Department of Anaesthesiology, Sankara Nethralaya  
No. 41(Old No. 18), College Road  
Chennai 600006, Tamil Nadu India  
Email: drvvj@snmail.org

### Article History

Received: 4<sup>th</sup> April 2021

Revision: 29<sup>th</sup> April 2021

Accepted: 10<sup>th</sup> June 2021

Published: 30<sup>th</sup> June 2021

STB was introduced into the clinical practice as a simple, safe, and effective technique because of continuing concerns over the rare but serious complications like globe perforation associated with sharp needle blocks. A few observational studies involving large number of patients report a low rate of serious ocular and systemic complications with STB.<sup>7,8</sup> There was only one instance of a non-sight threatening subconjunctival haemorrhage in a retrospective study of 6,000 patients who underwent STB.<sup>8</sup> However, there have been several case reports of severe ocular and systemic complications with STB.<sup>9-16</sup> To date, no randomized controlled trial has been published to prove that STB has less risk of serious complication than traditional needle blocks.<sup>17</sup>

In the opinion of first author, who have been practicing needle blocks for over two decades, following are the factors which favors PBB.

### Pros

- i) PBB avoids the need for dissection of conjunctiva and breaching the anatomical integrity of the eyeball layers.
- ii) PBB is easy to administer and does not require the use of forceps or scissors.

**How to cite this article:** Peribulbar blocks – Pros Vs Cons: A debate. Jaichandran V V, Keith Allman. *Ind J Ophthal Anaesth* 2021;1(2):38-44

- iii) Patient's cooperation is not a major pre-requisite. Hence, in patients requiring sedation, PBB is better.
- iv) PBB is easier to administer in patients who have sunken eyes (deep socket, deep seated eye) or those who cannot lie completely flat for any reason.
- v) PBB can be done without any prior instillation of local anaesthetic drops into the eye.
- vi) PBB is preferable in patients with a previous 'band' or scleral buckle, glaucoma drainage devices, and lesions of conjunctiva such as pterygium.
- vii) PBB has a very low incidence of chemosis and subconjunctival haemorrhage. Hence, the eye does not appear bruised after the block. For e.g., cataract surgery involves a 3 mm incision. PBB maintains the appearance of the eye.
- viii) Use of single medial injection PBB virtually eliminates the risk of globe perforation in myopic patients as almost all staphylomas are lateral or posterior.
- ix) PBB is safe even in patients on anticoagulation and multiple studies have shown that the incidence of bleeding is either not increased or is not of clinical significance.
- x) PBB is cost effective as it obviates the need for forceps and scissors.

One dreaded complication of a sharp needle block is globe perforation (GP) and ideally should never happen. Its incidence is much lower in PBB when compared to retrobulbar blocks.

The incidence of GP due to PBB is not negligible and was about 1 in 4500 in the last UK survey conducted in 2012-13.<sup>7</sup> However, this can be reduced significantly if not eliminated with better training, use of simulators, and possibly by increased use of single medial injection PBB. To date, there have been no reports of GP with single medial injection PBB.<sup>18</sup> To develop and improve their skills in administering needle blocks, modules such as Ophthalmic Anaesthesia Simulation System (OASiS)<sup>19</sup> and real time view mannequin<sup>20</sup> can be considered. Ultrasound guided blocks are likely to increase in future and may improve safety.

An important question for me "Is the risk of a GP sufficient not to have a PBB"? I do not think so. To put it in perspective, the risk of death after coronary catheterization is quoted as 0.02%<sup>21</sup>. The risk of stroke after coronary catheterization ranges from 0.08% - 0.38%<sup>22</sup>. Even if I take the lowest risk of stroke, combining it with mortality figures gives a risk of 0.05% of a major complication i.e. 1 in 2000. That is still more than double the risk of GP. Considering the advantages of PBB and the relatively low risk, I do not mind having a PBB. Like any other patient, I will pray that the person performing is reasonably trained.

## “Peribulbar block - Cons”

### Introduction

In any debate one must take sides - often more ardently than is practicable in real life. The following represents second author's own experience of ophthalmic anaesthetic blocks. It is based upon UK practice generally. These do not necessarily represent the opinions of BOAS as a whole and are in no way intended to cause offence to anyone especially my esteemed colleague and good friend, who is on the other side of this debate. Like many other UK ophthalmic centres, until about 15 years ago, most of our routine work was undertaken using peribulbar block (PBB) – considered (correctly) a significant improvement in safety over the much too prevalent retro-bulbar block. An inadvertent globe perforation (GP) caused us to rethink our unit policy. The case was particularly poignant as it involved a trainee anaesthetist who was psychologically traumatised, and a professional gentleman recently retired to take up his hobby of water-colour painting. In discussion with our surgical colleagues, we re-examined the available evidence for all options of ophthalmic anaesthesia, and within a matter of weeks had largely dropped all sharp needle blocks in favour of subtenon block (STB). They have never been missed!

### Cons

PBB is an extremely easy and effective anaesthetic technique (there – I have said it). Most anaesthetists who have done it for several years never experience a serious complication. Unfortunately, this ‘micro’ view is somewhat limiting and if one ‘steps back’ and takes a wider national view, a rather different story becomes apparent. Tom Eke et al. have done exactly that – three times. Using data obtained through the British Ophthalmological Surveillance Unit at the Royal College of Ophthalmologists, London, they undertook incidence studies of complications relating to ophthalmic anaesthesia. Through each time period examined, the rate of GP related to PBB was remarkably consistent at around 2/10,000.<sup>23,24,25</sup> This figure is conservative as the studies relied on a degree of self-reporting. It is low enough for individual anaesthetists performing normal numbers of blocks to rarely see a sight threatening complication, but large enough to have significant detrimental effects on a population scale. In the UK more than 300,000 cataract operations are performed annually, and if all these were undertaken using PBB then we would expect at least 60 GP each year. The USA performs more than 3,000,000 cataracts annually and this would equate to 600 GP a year. GP as a complication of PBB is usually not recognised immediately and is often catastrophic for vision.

And this is not the most common complication of sharp needle blocks. Serious sight threatening retrobulbar haemorrhage occurs with a similar incidence to GP, and direct muscle damage from sharp needles, which will often result in debilitating diplopia requiring lens or surgical correction, occurs with a conservatively estimated rate of 0.25% (25/10,000).<sup>26</sup>

### **Is PBB safe in my hands and much cheaper?**

There is no doubt that with experience the incidence of GP with PBB can be reduced. Roy Hamilton (undoubtedly a leading world expert on PBB) is apocryphally said to have performed 40,000 blocks before experiencing a GP. Unfortunately, not all practitioners are so lucky nor so experienced. Teaching other anaesthetists or trainees the technique will inevitably cause an increased incidence, and the presence of several unknowns (staphyloma, distorted anatomy) means that sharp needle techniques always contain an element of "Russian Roulette".

The argument that PBB is cheaper than, for example, STB is also fallacious. A case of inadvertent GP recently settled out-of-court for £100,000 plus costs (personal communication). Assuming an incidence of 2/10,000; this means that every PBB undertaken in the UK is likely to be costing the NHS at least £20 in subsequent medico-legal costs. The opinions of the legal team involved in this case are salutary.

The crux of the case revolved not around the Bolam principle, but on whether proper informed consent had been taken.

It was felt that as sight loss is a well-recognised complication of PBB, informed consent should include a realistic discussion of these risks together with an appraisal of the use of other potentially safer methods of achieving anaesthesia (STB, general anaesthesia, infiltration etc). This is a difficult discussion to undertake possibly twenty times per day – not to mention time consuming.

### **What is wrong with STB?**

Many of those anaesthetists steadfastly adhering to sharp needle techniques will argue that STB is difficult to learn, does not give akinesia and causes unacceptable amounts of low-grade morbidity (chemosis and sub-conjunctival haemorrhage). They often also state that their surgeons 'don't like it'. The first point is true – STB is much harder to learn and teach than PBB. The other points, however, are not. With experience and a good technique, STB will give reliable, full akinesia with little or no haemorrhage (particularly if using an "incisionless technique").<sup>27</sup> A small degree of chemosis is almost inevitable but can be reduced to acceptable levels. It should also be remembered that many PBB also cause significant chemosis. Surgical opinion is difficult, and I believe it is important that if changes to ophthalmic anaesthetic technique are to be made, it is best to do this in conjunction with surgical colleagues. In our institution, once the risk / benefit discussion had been clearly presented, our ophthalmologists were absolutely in favour



of a change that would clearly and directly benefit patients. Since changing to using exclusively STB anaesthesia almost fifteen years ago, we have never been asked to perform PBB, and we have never felt the need to.

### Conclusion

Perhaps the most important part of any technique is not the equipment or method used per se, but the person behind the cannula or needle. Our speciality is no longer simple – expectations from both surgeons and patients have increased dramatically in the past twenty years. Surgical techniques have become ever more challenging, in a patient population of advancing years. Perhaps the most important change should be that we have anaesthetists who are interested in, and competent at, all available methods of ophthalmic anaesthesia: anaesthetists who work regularly in eye theatres for more than one session a week and those who have the experience of day-to-day running of an eye unit. Then, perhaps, I might, just possibly, entertain the merest idea, of letting someone near my eye with a sharp needle.

### Financial support and sponsorship

Nil.

### Conflicts of interest

There are no conflicts of interest.

### References:

1. The Royal college of Anaesthetists and the Royal college of Ophthalmologists. Local anaesthesia for intraocular surgery. The Royal college of Anaesthetists and the Royal college of Ophthalmologists. 2001.
2. Stephen J Mather, Kong KL, Shashi B Vohra. Loco-regional anaesthesia for ocular surgery. Anticoagulant and antiplatelet drugs. *Current Anaesthesia and Critical care* 2010;21:158-63.
3. Katz J, Feldman MA, Bass EB, Lubomski LH, Tielsch JM, Petty BG. Study of medical testing for cataract surgery team. Risks and benefits of anticoagulants and antiplatelet medication use before cataract surgery. *Ophthalmology* 2003;110:1784-88
4. Leaming DV. Practice styles and preferences of ASCRS members 2003 survey. *J Cataract Refract Surg* 2004;30:892–900
5. Adeela Malik, Emily C. Fletcher, Victor Chong, Jay Dasan. Local anesthesia for cataract surgery. *J Cataract Refract Surg* 2010;36:133–52
6. Summer Singh, Rajiv Raman, Jaichandran. Practice pattern of regional ophthalmic anaesthesia in cataract surgery – A survey among Indian trainees. *EC Anaesthesia* 2020;6.9:03-08.
7. Lee RMH, Thompson JR, Eke T. Severe adverse events associated with local anaesthesia in cataract surgery: 1-year national survey of practice and complications in the UK. *Br J Ophthalmol* 2015;100:772-6

8. Guise PA. STB anesthesia: a prospective study of 6,000 blocks. *Anesthesiology* 2003;98:964-8
9. Frieman BJ, Friedberg MA. Globe perforation with STB anesthesia. *Am J Ophthalmol* 2001;520-1
10. Ruschen H, Bremmer FD, Carr C. Complications after STB eye block. *Anesth Analg* 2003;96:273-7
11. Olitsky SE, Juneja RG. Orbital haemorrhage after the administration of STB infusion anesthesia. *Ophthalmic Surg Lasers* 1997;28:145-6
12. Rahman I, Ataullah S. Retrobulbar haemorrhage after STB anesthesia. *J Cataract Refract Surg* 2004;30:2636-7
13. Jaycoco PD, Mather CM, Ferris JD, Kirkpatrick JN. Recuts muscle trauma complicating STB anaesthesia. *Eye* 2001;15:583-6
14. Spierer A, Schwalb E. Superior oblique muscle paresis after STB anaesthesia for cataract surgery. *J Cataract Refract Surg* 1999;25:144-5
15. Redmill B, Sandy C, Rose GE. Orbital cellulitis following corneal gluing under STB local anaesthesia. *Eye* 2001;15:554-7
16. Patel B, Jenkins L, Benjamin L, Webber S. Dilated pupils and loss of accommodation following diode pan retinal photocoagulation with STB local anaesthesia in four cases. *Eye* 2002;16:628-32
17. Kumar CM. Orbital regional anesthesia: Complications and their prevention. *Indian J Ophthalmol* 2006;54:77-84
18. Kannan S. Should single medial canthus injection be the default option for peribulbar blocks? 2018;62:321-2
19. Biswarup M, Jaichandran VV, Bobby G, Mohanasankar S. Evaluation of an Ophthalmic Anesthesia Simulation System for Regional Block. *Ophthalmology* 2015;122(12):2578-80
20. Nimal JK, Jaichandran VV, Bobby G, Mohanasankar S. Visual Feedback Enabled Training Mannequin for Ophthalmic Blocks: an Evaluative Study. *Proceedings Cairo Inter-national Biomedical Engineering Conference (CIBEC), Cairo, Egypt* (2018):82-5
21. Ercan S, Kaplan M, Aykent K, Davutoglu V. Sudden death after normal coronary angiography and possible causes. *BMJ Case Rep.* 2013; bcr2013008753. doi:10.1136/bcr-2013-008753
22. Dukkupati S, O'Neill WW, Harjai KJ, Sanders WP, Deo D, Boura JA. Characteristics of cerebrovascular accidents after percutaneous coronary interventions. *J Am Coll Cardio.* 2004;43:1161-7
23. Eke T, Thompson J. The national survey of local anaesthesia for ocular surgery. I. Survey methodology and current practice. *Eye* 1999;13:189-95
24. Eke T, Thompson J. Serious complications of local anaesthesia for cataract surgery: a 1 year national survey in the United Kingdom. *Br J Ophthalmol* 2007;91(4):470-5
25. Lee R, Thompson J, Eke T. Severe adverse events associated with local anaesthesia in cataract surgery: 1 year national survey of

practice and complications in the UK Br J  
Ophthalmol 2016;100(6):772-6

26. Anaesthesia-related diplopia after  
cataract surgery J. I. Gómez-Arnau, J.  
Yangüela, A. González, Y. Andrés, S.  
García del Valle, P. Gili, J. Fernández  
-Guisasola, A. Arias Br J Anaesth  
2003;90(2):189-93

27. Allman KG, Theron A, Byles DB. A new  
technique of incisionless minimally  
invasive sub-Tenon's anaesthesia.  
Anaesthesia 2008;63:782-3



## Association of Indian Ophthalmic Anaesthesiologists

Organization in which Anaesthesiologists, Ophthalmologists and  
Clinicians involved in Eye care can share their views under one roof

To know more about its Objectives and Privileges of becoming its MEMBER,  
<http://aioa.org.in/>

  
**Dr Parakh SC**  
President

  
**Dr Jaichandran VV**  
Secretary

  
**Dr Kannan R**  
Treasurer



**IJOA** Indian Journal of  
Ophthalmic Anaesthesia  
Volume 1 Issue 2 June 2021

**Next IJOA issue will be released on-line  
on Jan 2022.**

I Kindly request the members to submit  
article (Original article / Case report /  
Brief communication/ Letters) to  
[editorijoa@gmail.com](mailto:editorijoa@gmail.com)

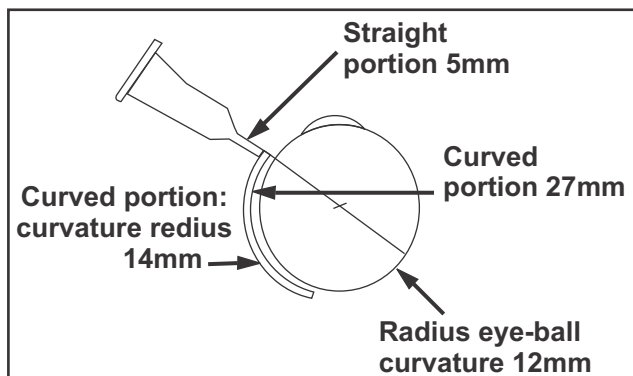
**Dr Renu Sinha**  
Editor, Indian Journal of Ophthalmic Anaesthesia, IJOA

Official Journal of  
Association of Indian Ophthalmic Anaesthesiologists, AIOA  
Old No. 16, New No. 45, College Road, Chennai 600 006.  
[www.aioa.org.in](http://www.aioa.org.in)

## Muthusamy Sub-Tenon's Cannula: An Untold Story - II

Dear Sir / Madam,

For those readers who read with interests the initial story about my cannula, here is the rest of the untold story. A brief description about the cannula:



It has a straight portion and a curved portion, figure 1. The straight portion is 5 mm long and the curved portion is 27 mm long. The straight portion of the cannula is tangentially angled to the curved portion. It is easily visualized while the curved portion of the cannula is completely in the sub-Tenon's space. The junction of the two portions will help the surgeon to know when to stop the entry of the cannula into the sub-Tenon's space and where the tip of the cannula will be.

### Address for correspondence:

Prof Muthusamy P  
MBBS, DO (Lond), FRCSEd, FRCOphth  
FICO  
Muthu Eye Clinic and Surgery Kota  
Kinabalu Specialist Centre  
Kota Kinabalu, Malaysia

### Article History

Received: 15<sup>th</sup> March 2021

Revision: 20<sup>th</sup> April 2021

Accepted: 15<sup>th</sup> June 2021

Published: 30<sup>th</sup> June 2021

The radius of curvature of the curved portion is 14 mm. As the average radius of the eye ball is 12 mm, it makes the cannula to almost hug the eye ball and remains precisely in the sub-Tenon's space. The length of the curved portion is 27 mm long so that it will be about 5 mm away from the optic nerve, and will not damage the optic nerve. The bore of the cannula is 24G, which is sufficiently wide to easily deliver the anaesthetic solution. The tip is blunt and slightly flattened. The blunt tip prevents any iatrogenic injury occurring to the globe. The flat tip facilitates the smooth entry of the cannula into the sub-Tenon's space and thus it is quite easy to use.

This cannula is manufactured by Zabby (<http://www.zabbys.net/>) in India.<sup>1</sup> When Prof David Guyton in John Hopkins started using my cannula, I became confident that my cannula will become famous all over the world. I promoted my cannula with alacrity through my students all over the world. I learned from the manufacturer that he was selling a fair amount to ophthalmologists all over the world. Though my colleagues nudged me to demand royalty, I refrained because Zabby was the only manufacture who took the trouble to manufacture and market it. I felt it was not morally right to make any demand.

While this cannula was gaining popularity, "Topical anaesthesia" for cataract surgery' was reintroduced. At its inception I was very skeptical about it. I hung on to Sub-Tenon for sometime but soon relented because, I found that the "Topical anaesthesia" was magician's wand which transformed



anesthesia for cataract surgery into a painless procedure. It made me to conclude that the era of sub-Tenon was over.

Later, in 2018, All India Ophthalmological Society (AIOS) annual meeting was held in Coimbatore, India. Zabby, the manufacturers, encouraged me to come for the conference to promote my cannula. I assumed that they were prepared to pay for my passage to Coimbatore to Kota Kinabalu, Malaysia. Not wanting to waste money, I explained to him, "There is no point in me going to Coimbatore. After the advent of "Topical anaesthesia, I don't think anyone would be interested in my cannula." He stunned me, "Sir, I am selling thousands of our cannula every year and it is being used all over world."

It never dawn on me that there are other ocular surgeries for which sub-Tenon cannula can be used! I was indeed thrilled and exalted to know that my cannula was not only "alive" but it was also thriving.

### **Financial support and sponsorship**

Nil.

### **Conflicts of interest**

There are no conflicts of interest.

### **Reference**

1.<http://www.zabbys.net/ophthalmic/muthusamy-subtenon-anesthisias-cannula.html>